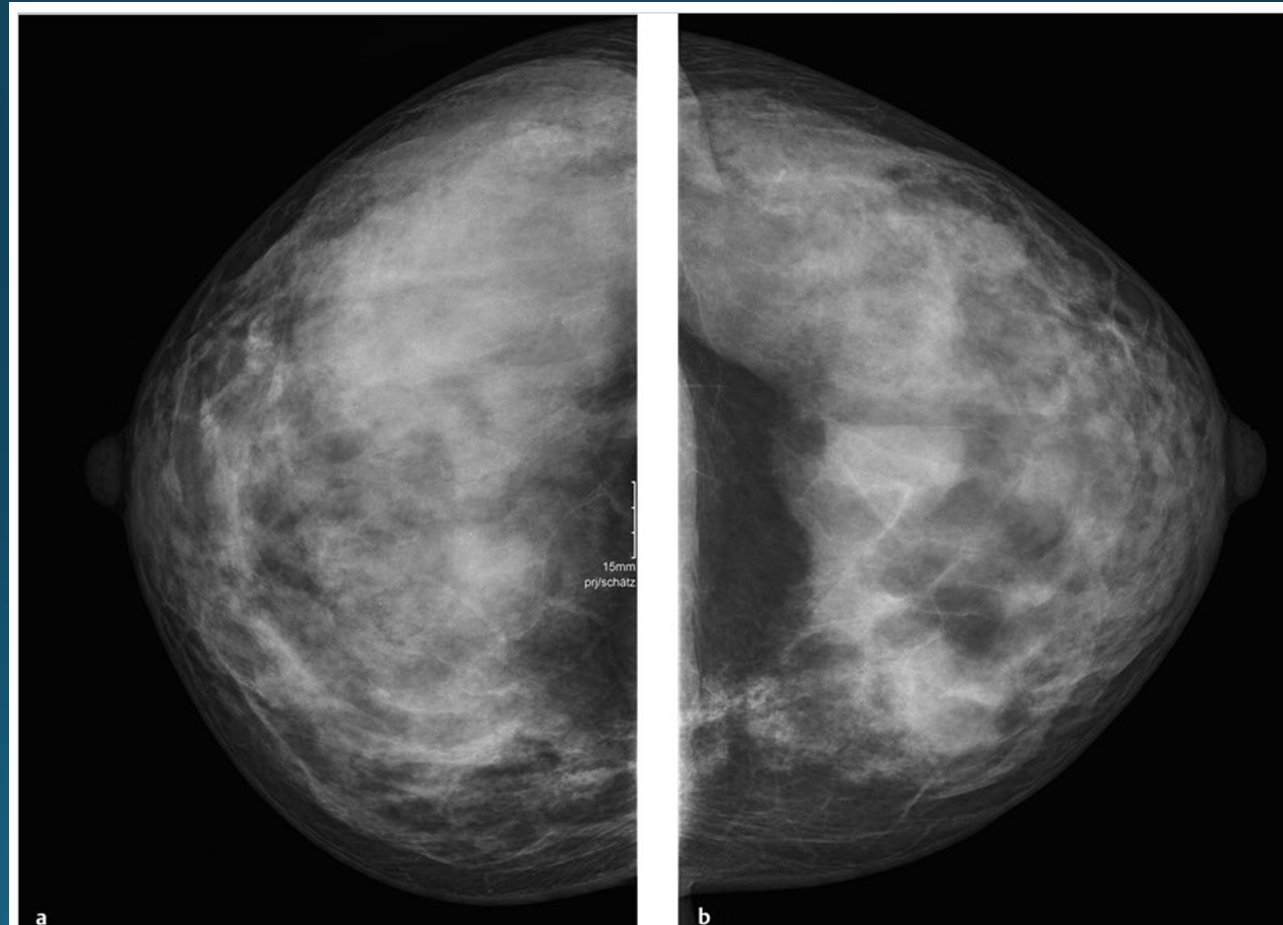
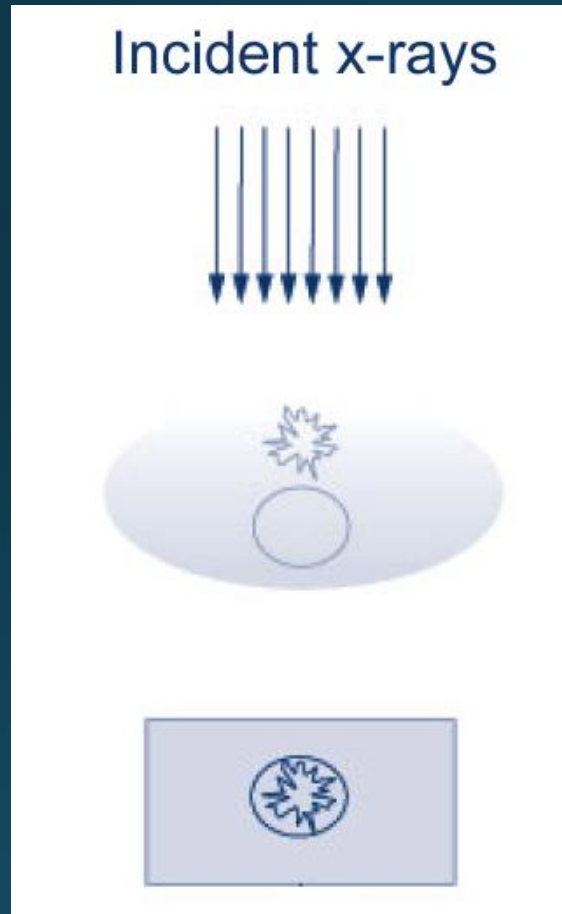


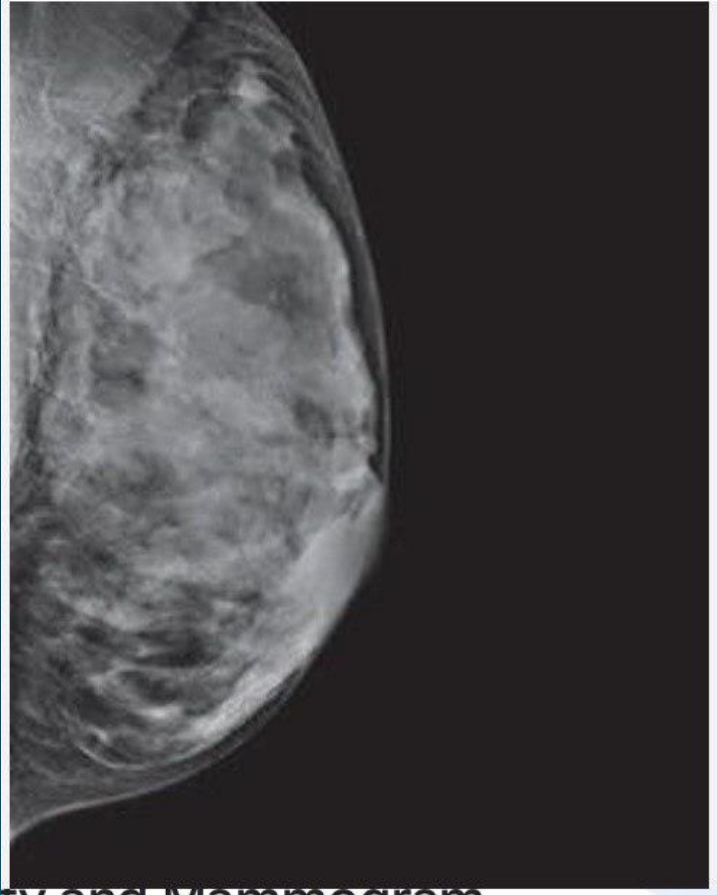
Dr.shahrzad dadgari

Digital breast tomosynthesis (DBT)

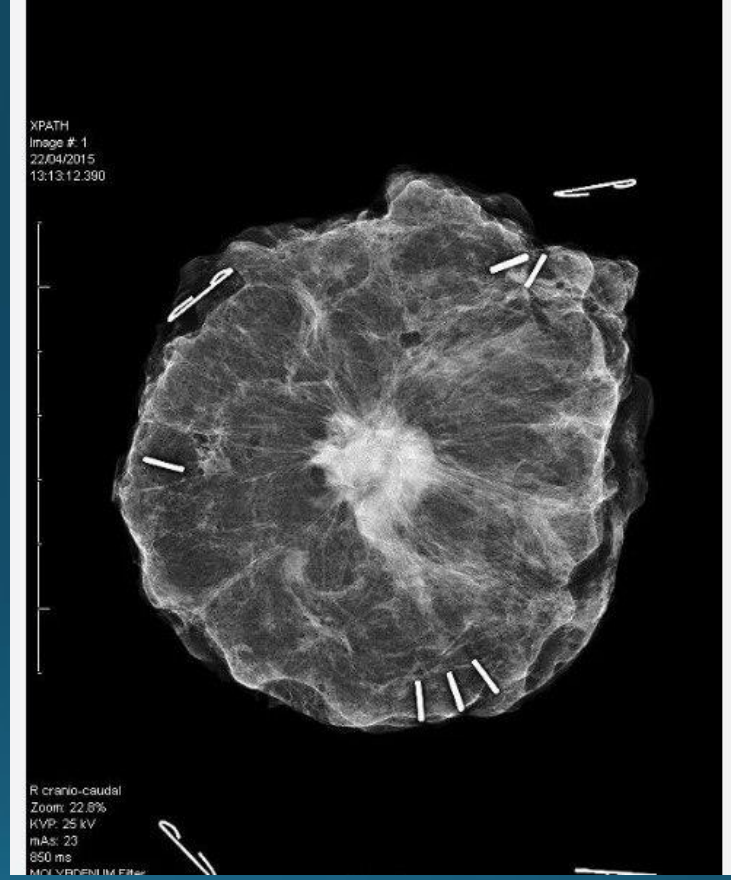
Mammography is a good tool for screening

Limitation of 2D-mammography





Mediolateral mammogram



Cranio-caudal mammogram


2D-mammography

- 20% false negative
- 70% biopsies are benign
- 10 % call back

Tomosynthesis (3D-mammography)

- Tomo : section
- Synthesis : elements form something new
- Three dimensional

Incident x-rays



Images as seen on cassette or digital detector

Individual Images



Individual Image Projection 1

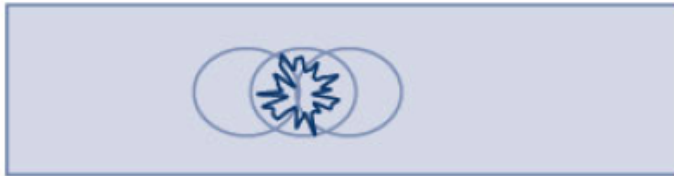

Individual Image Projection 2

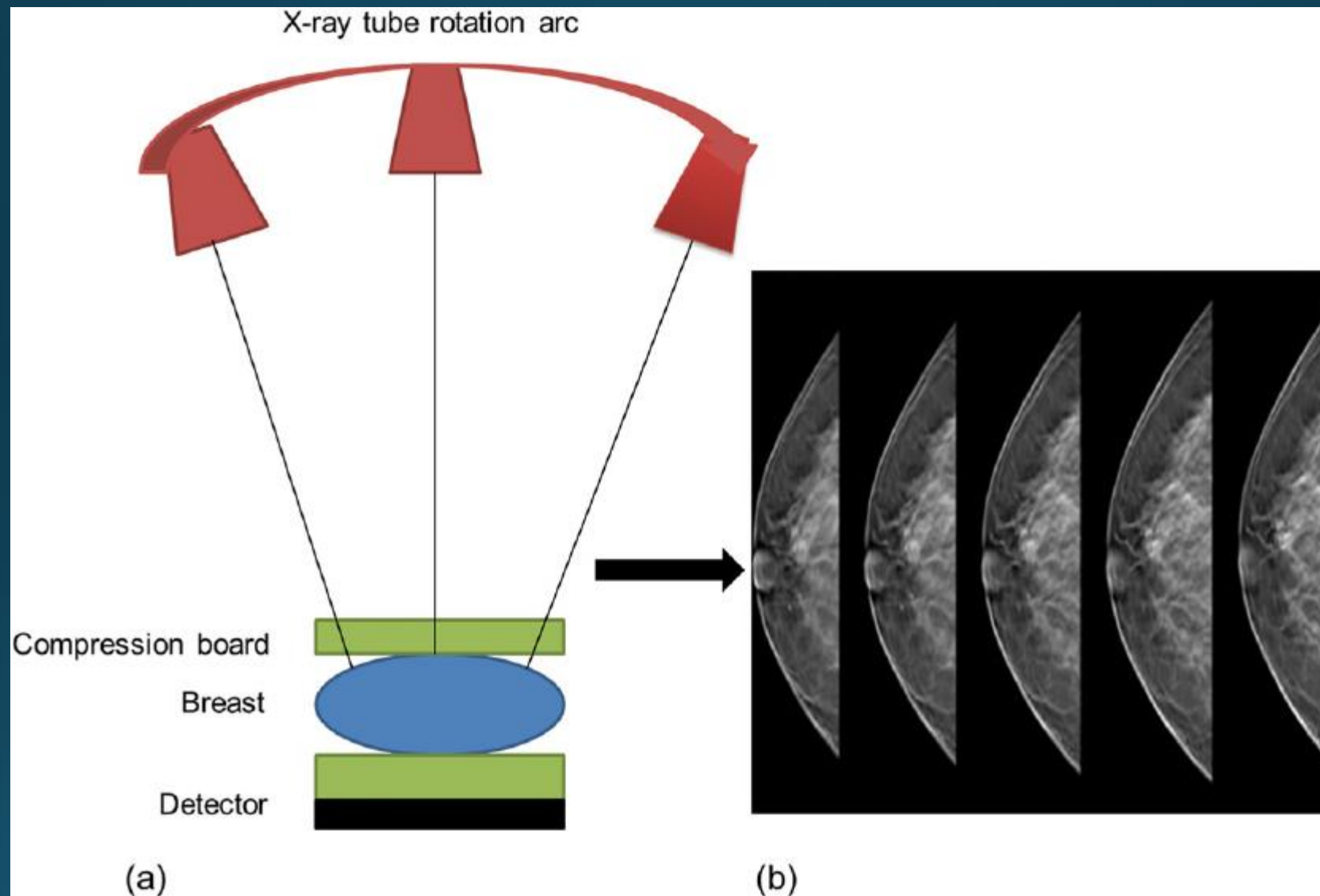


Individual Image Projection 3

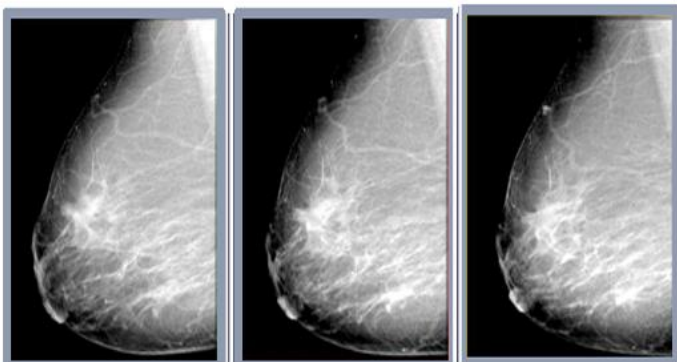
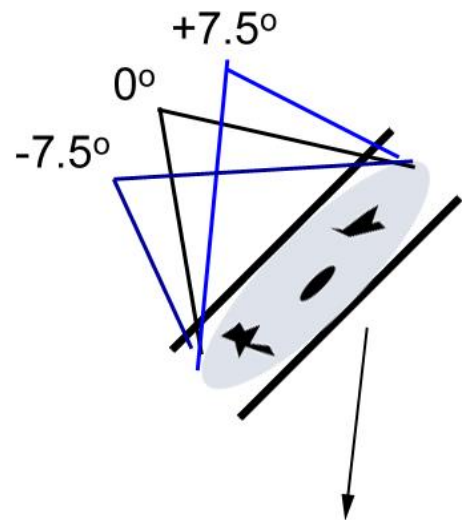
Synthesized Image



$1 + 2 + 3 = 1\text{mm Slice}$

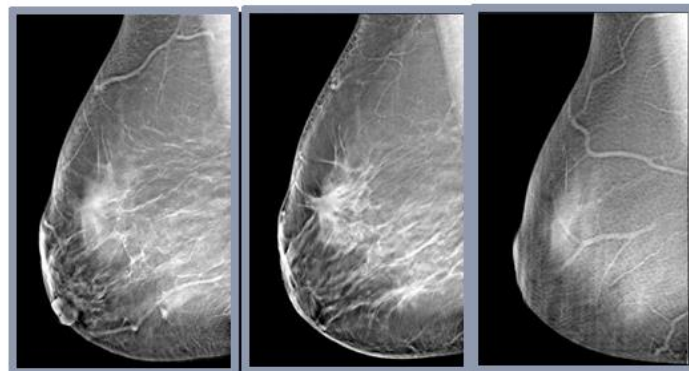
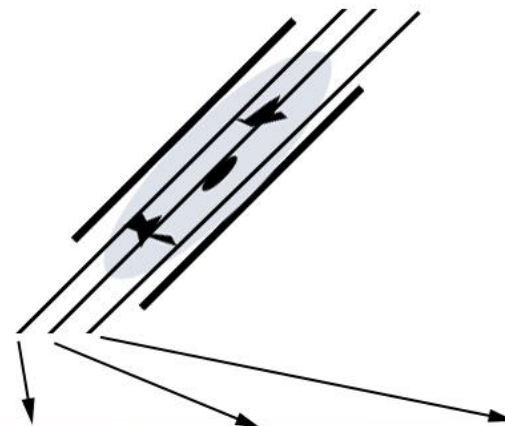


Projection images

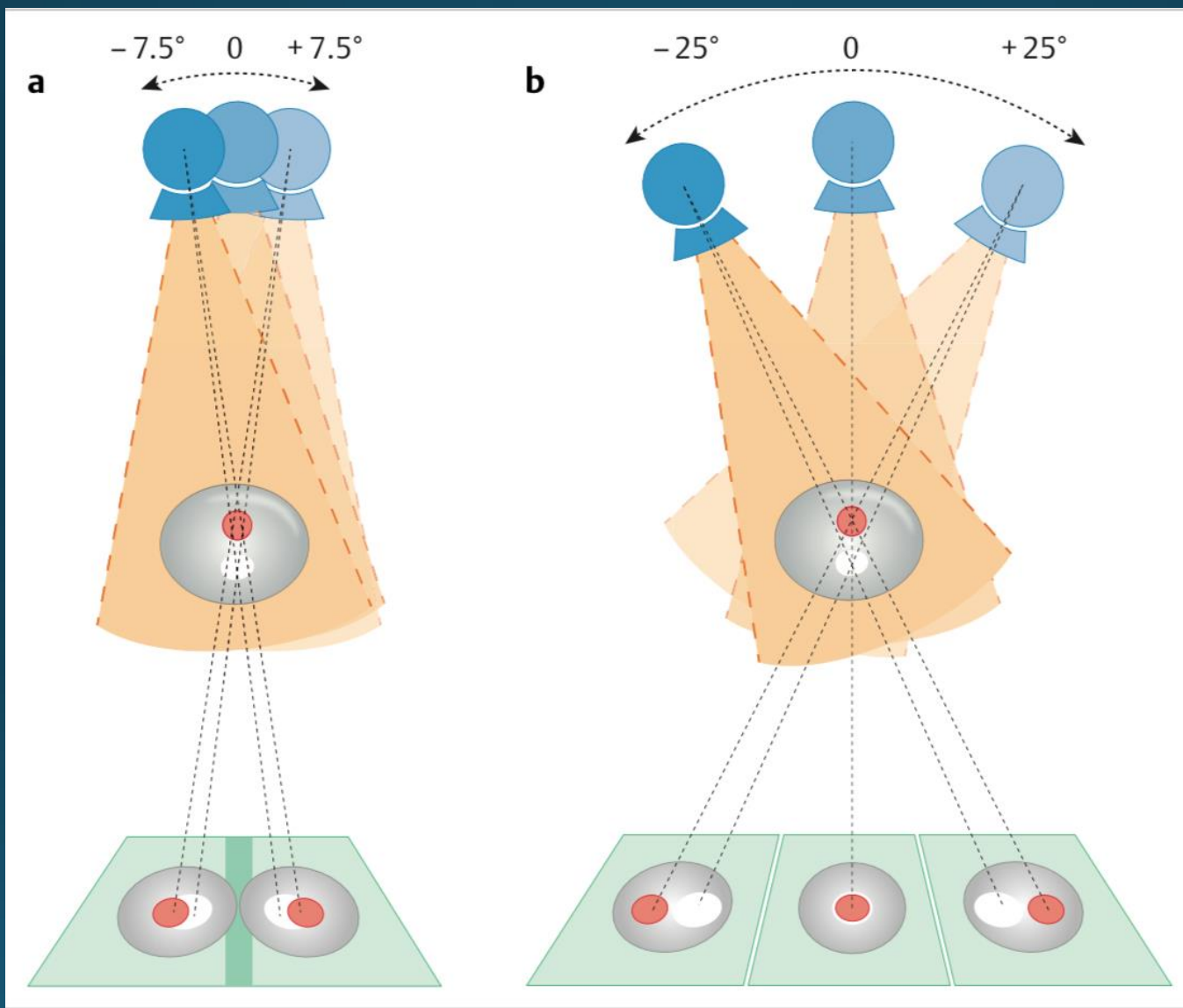


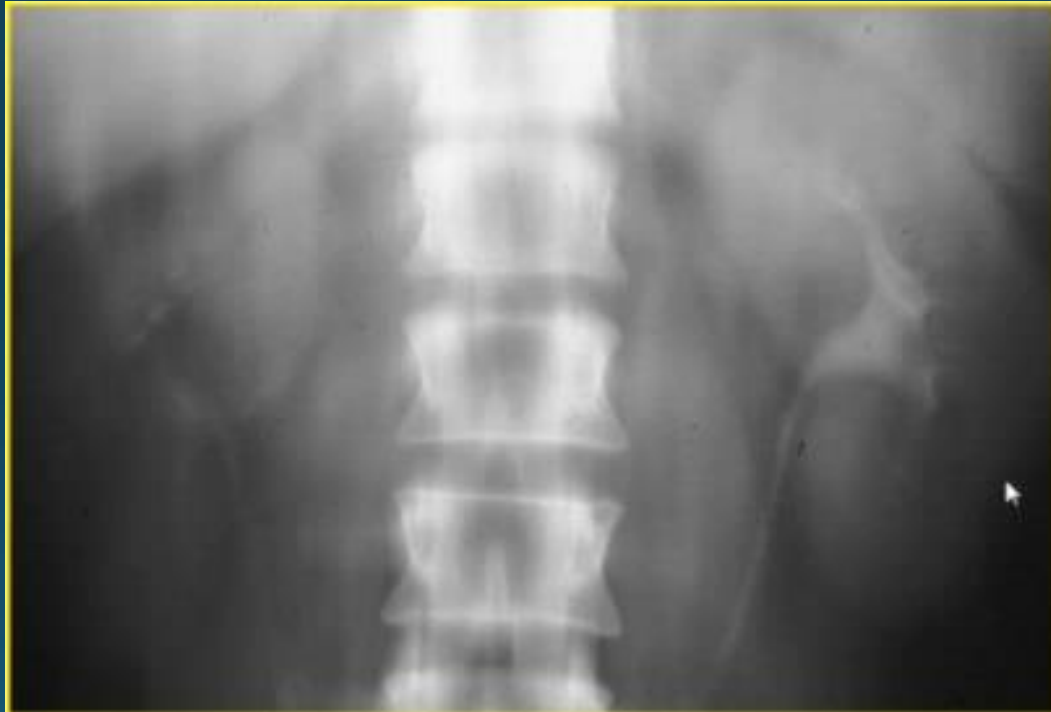-7.5° 0° $+7.5^\circ$
Views from different x-ray tube angles

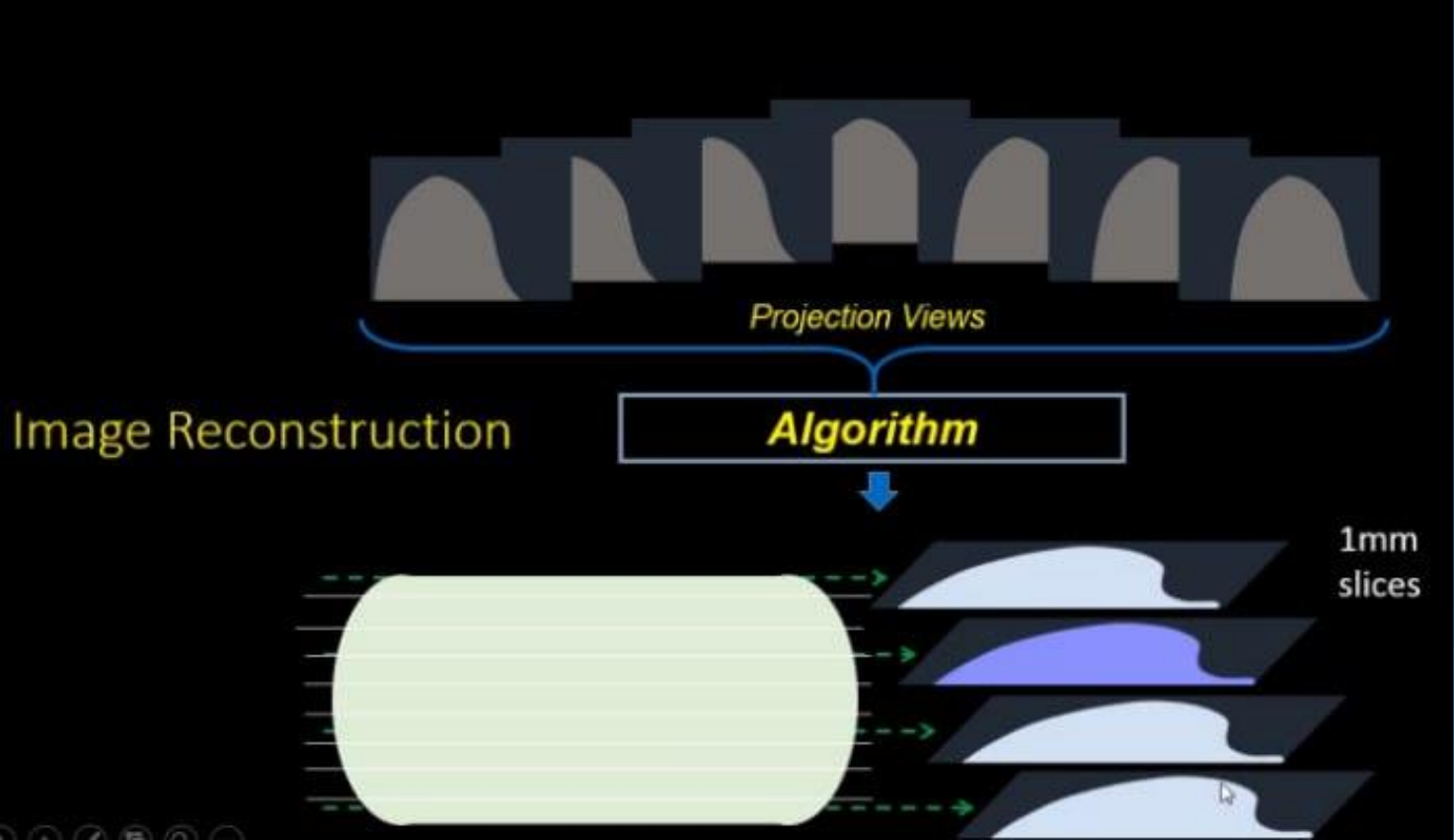
Reconstructed slices

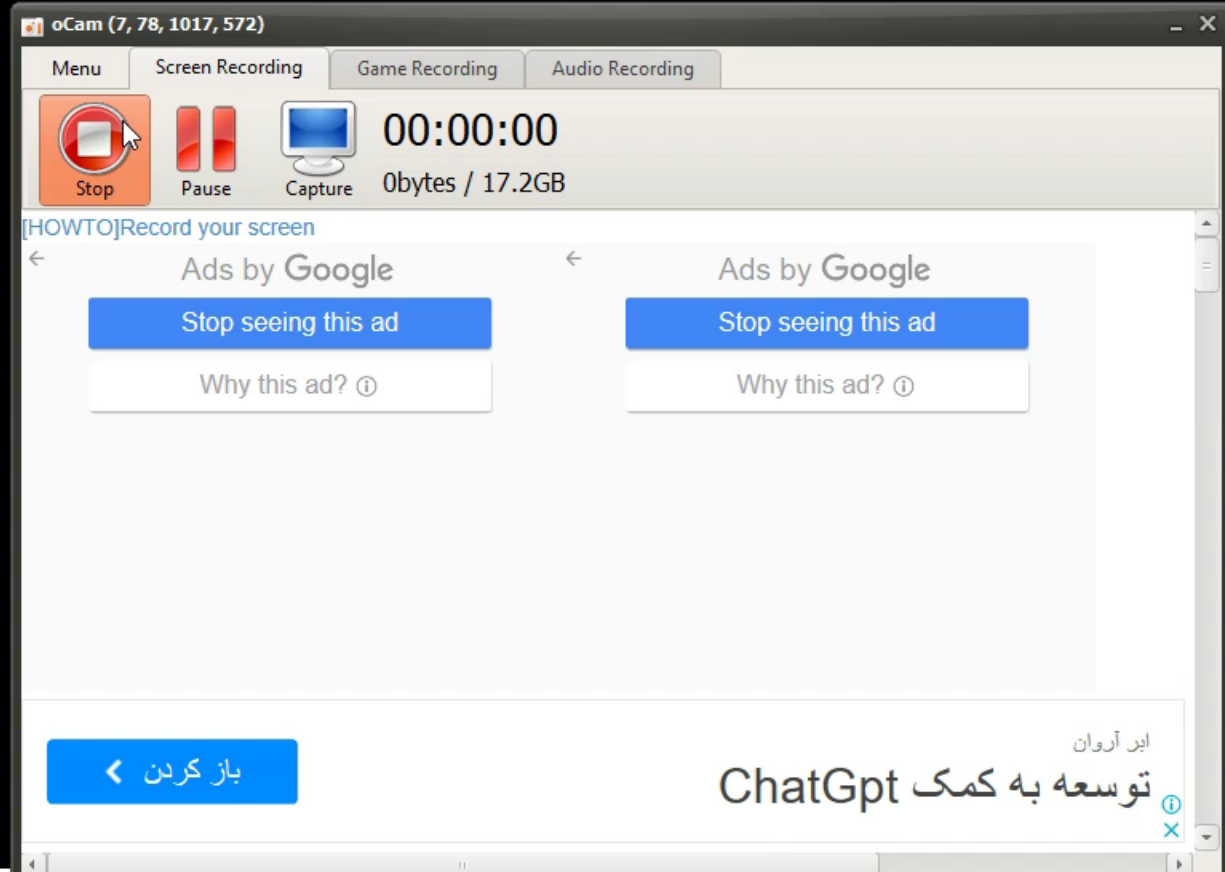


35 mm 25 mm 10 mm
Slices at different heights

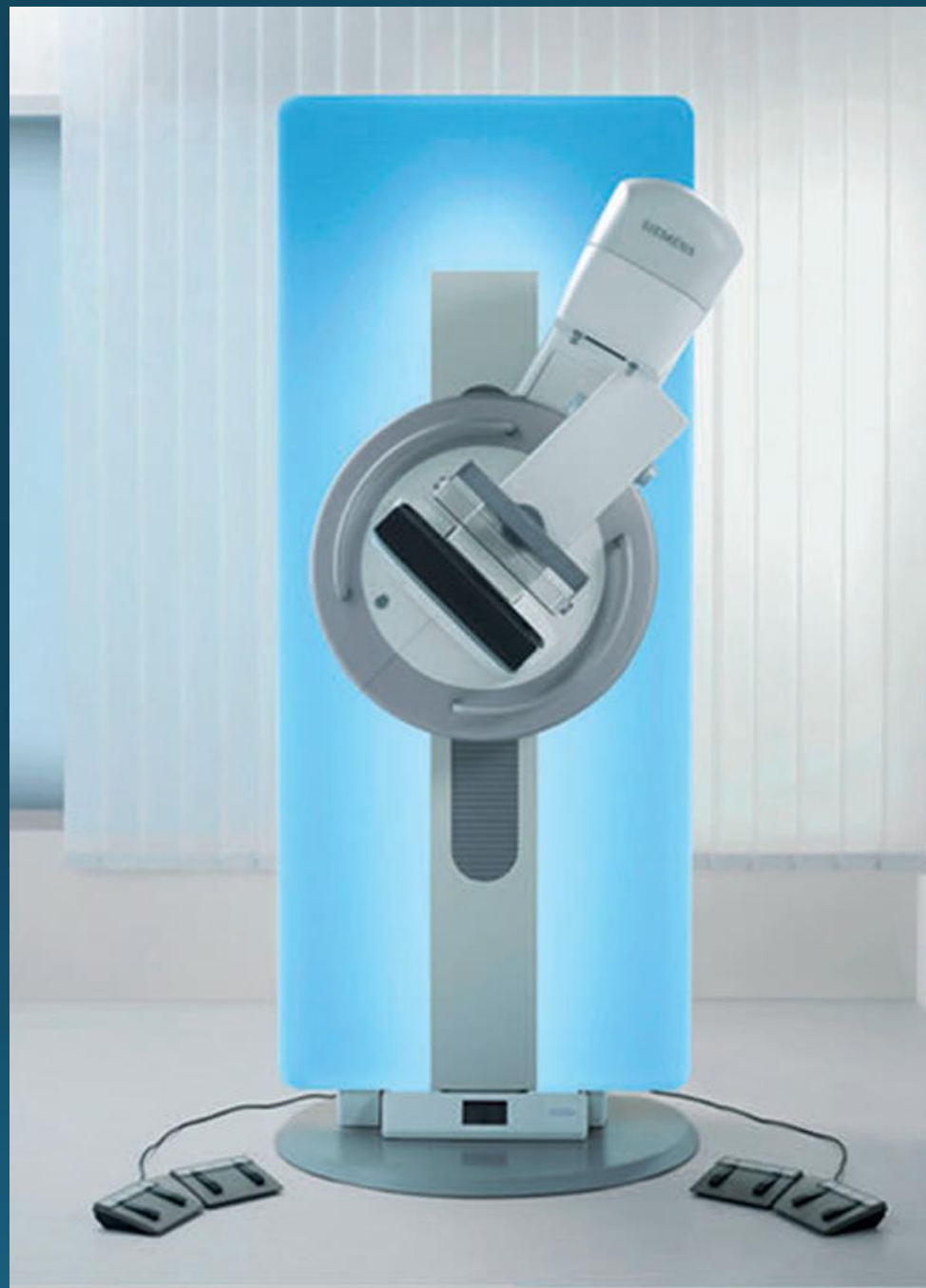







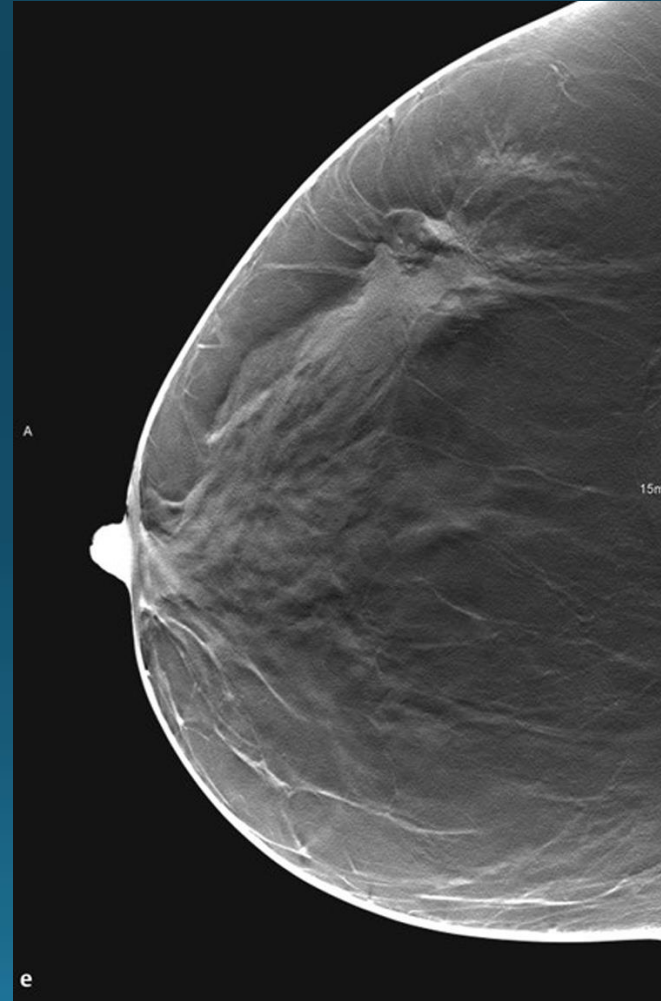
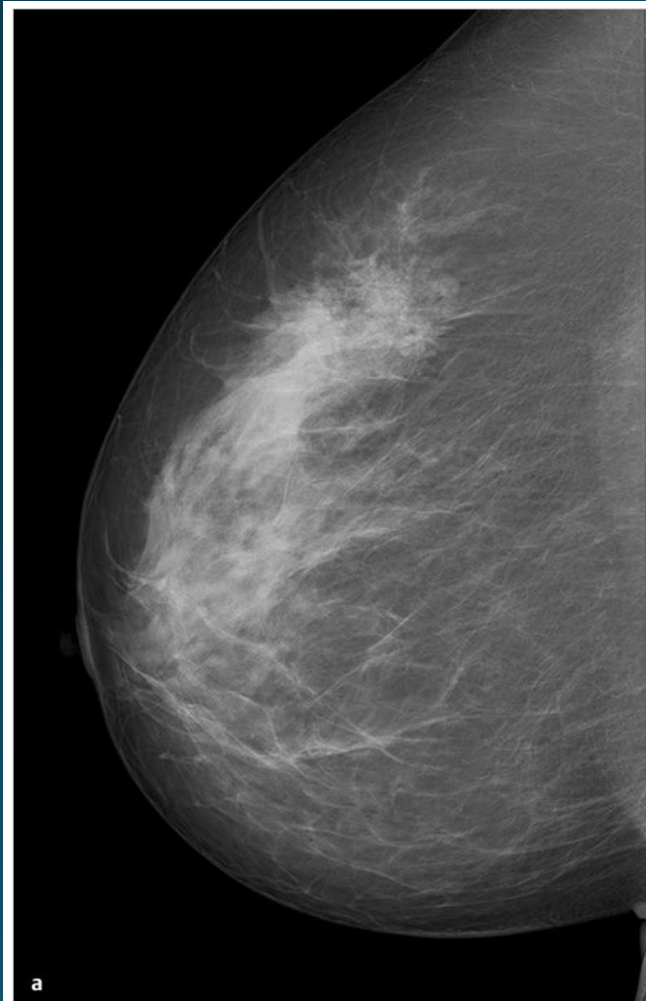




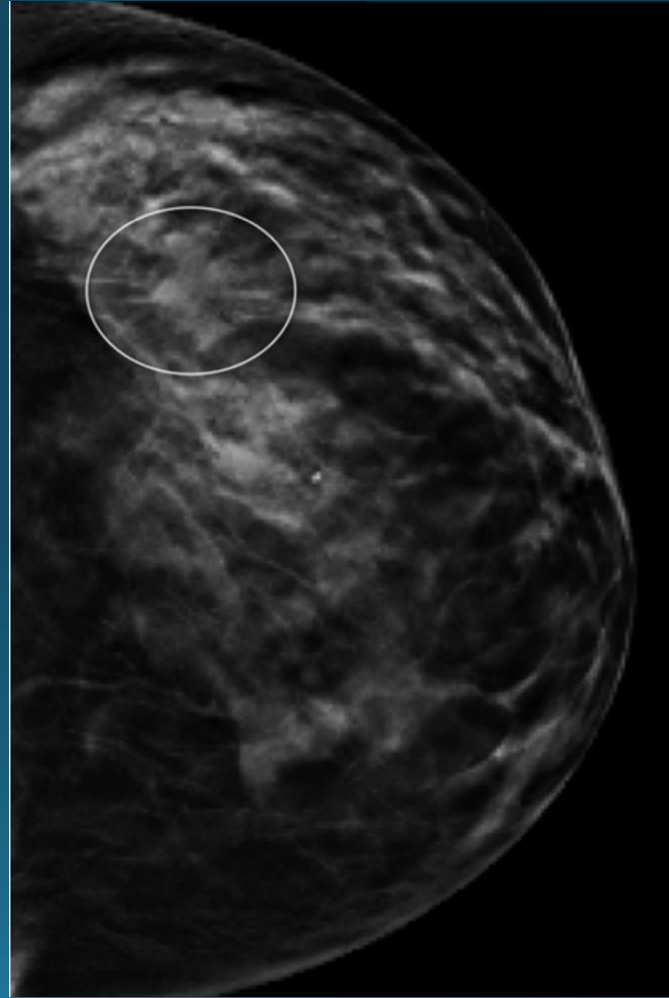
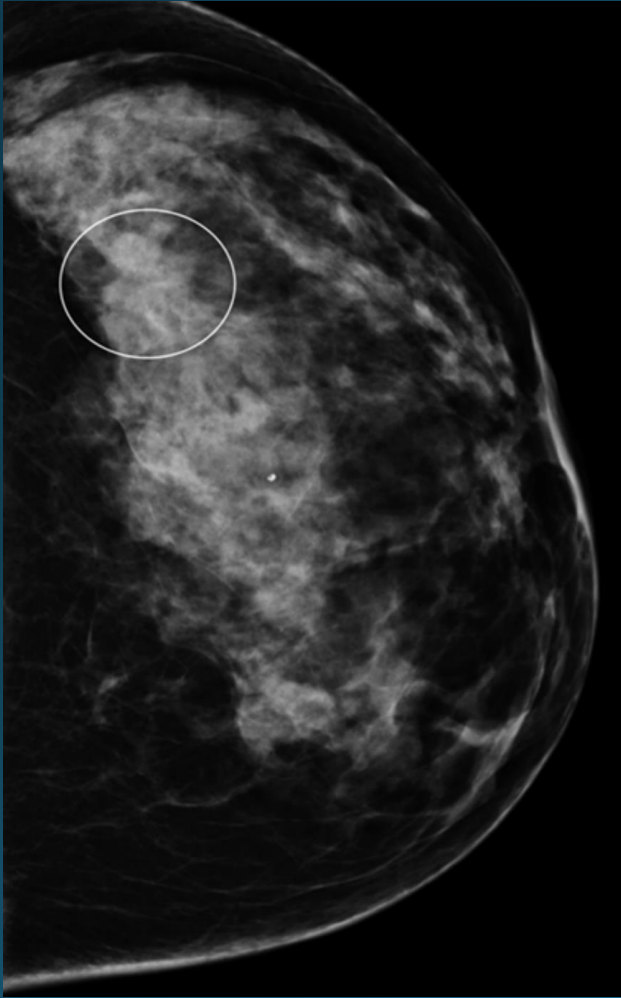
Parameters	GE Healthcare	Hologic Dimen- sions	IMS Giotto	Philips Microdose	Siemens Mammio- mat Inspiration
Status	CE-certified	CE-certified	CE-certified	Prototype	CE-certified
Tomosynthesis angle	25°	15°	40°	11°	50°
Number of projections	9	15	13	21	25
Tube motion	Step & shoot	Continuous	Step & shoot	Continuous	Continuous
Scan time (s)	7	4	12	3–10	25
Detector size (cm ²)	24 × 30	24 × 29	24 × 30	Multiple line detec- tors	24 × 30
Detector pixel (μm)	100	140	85	50	85
X-ray converter	CsI/a-Si	a-Se	a-Se	Si	a-Se
Radiation	Rh/Rh	W/Al	W/Rh	W/Al	W/Rh

DBT advantage

1-improve sensitivity (overlapping tissue)

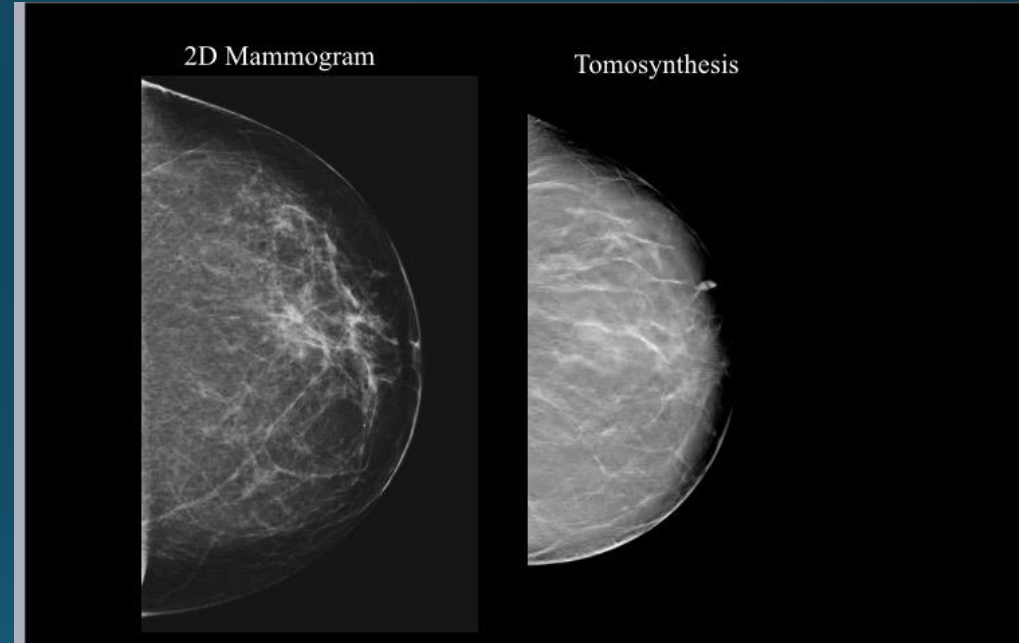


a. Increased cancer detection rate

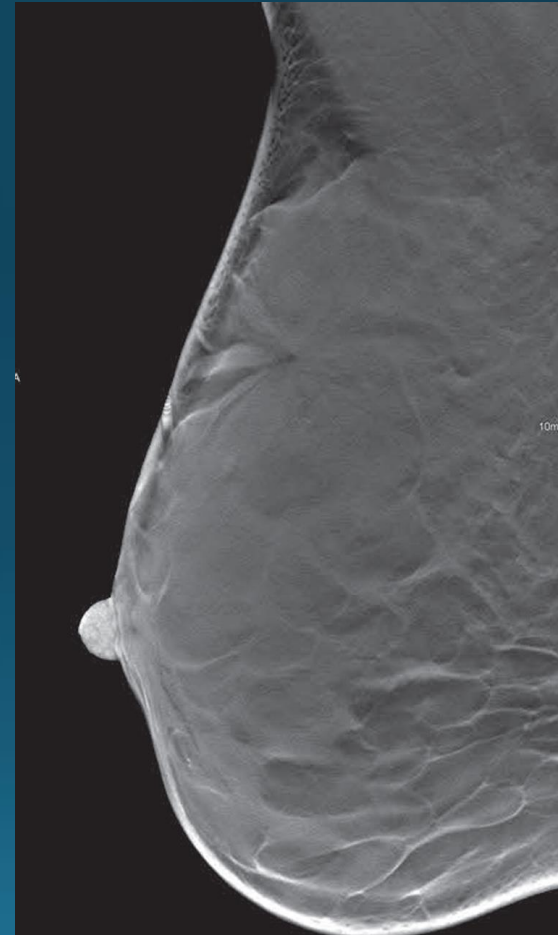
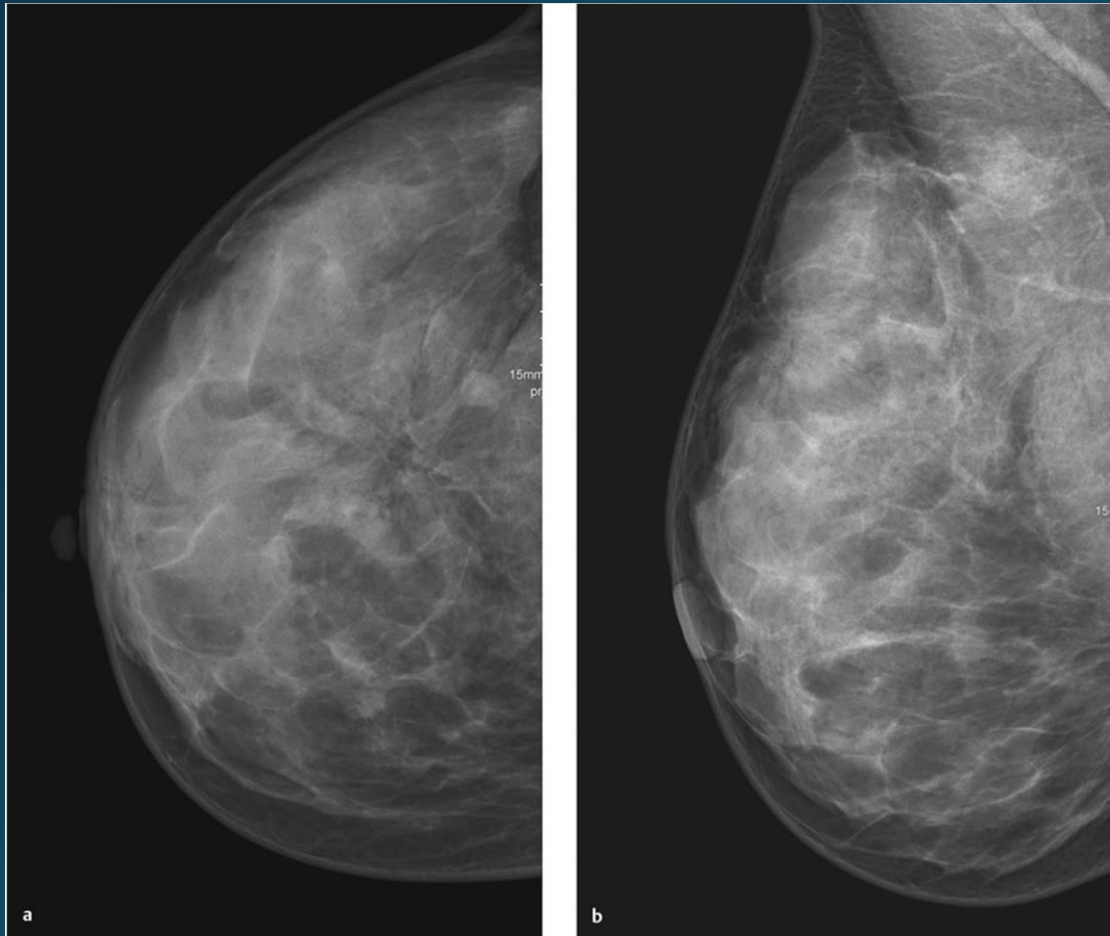


b. Small invasive cancer

- Additional cancers are primarily Invasive , small , node negative
Good prognosis cancer



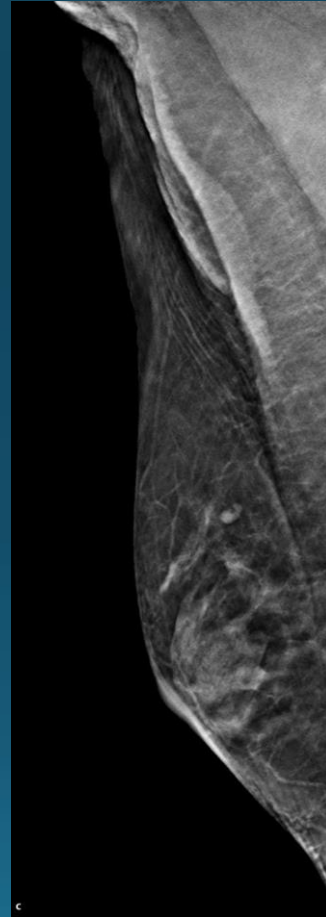
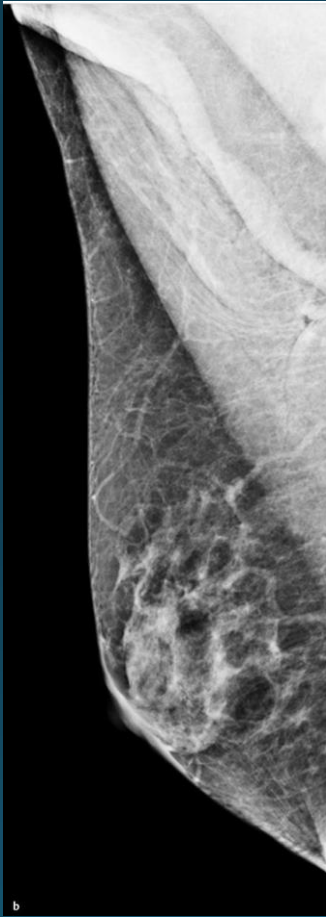
c. Increased detection of AD



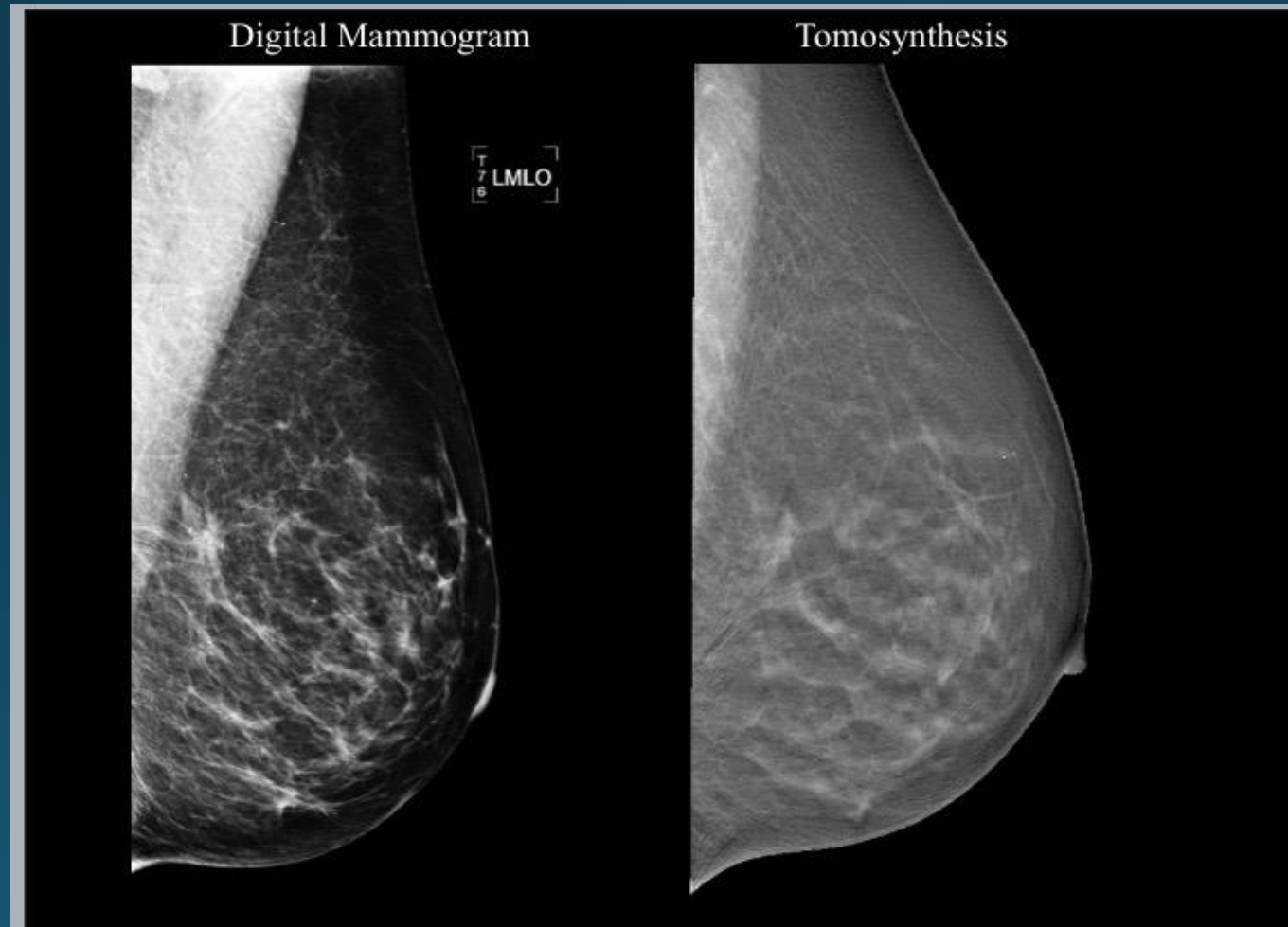Increased detection of AD

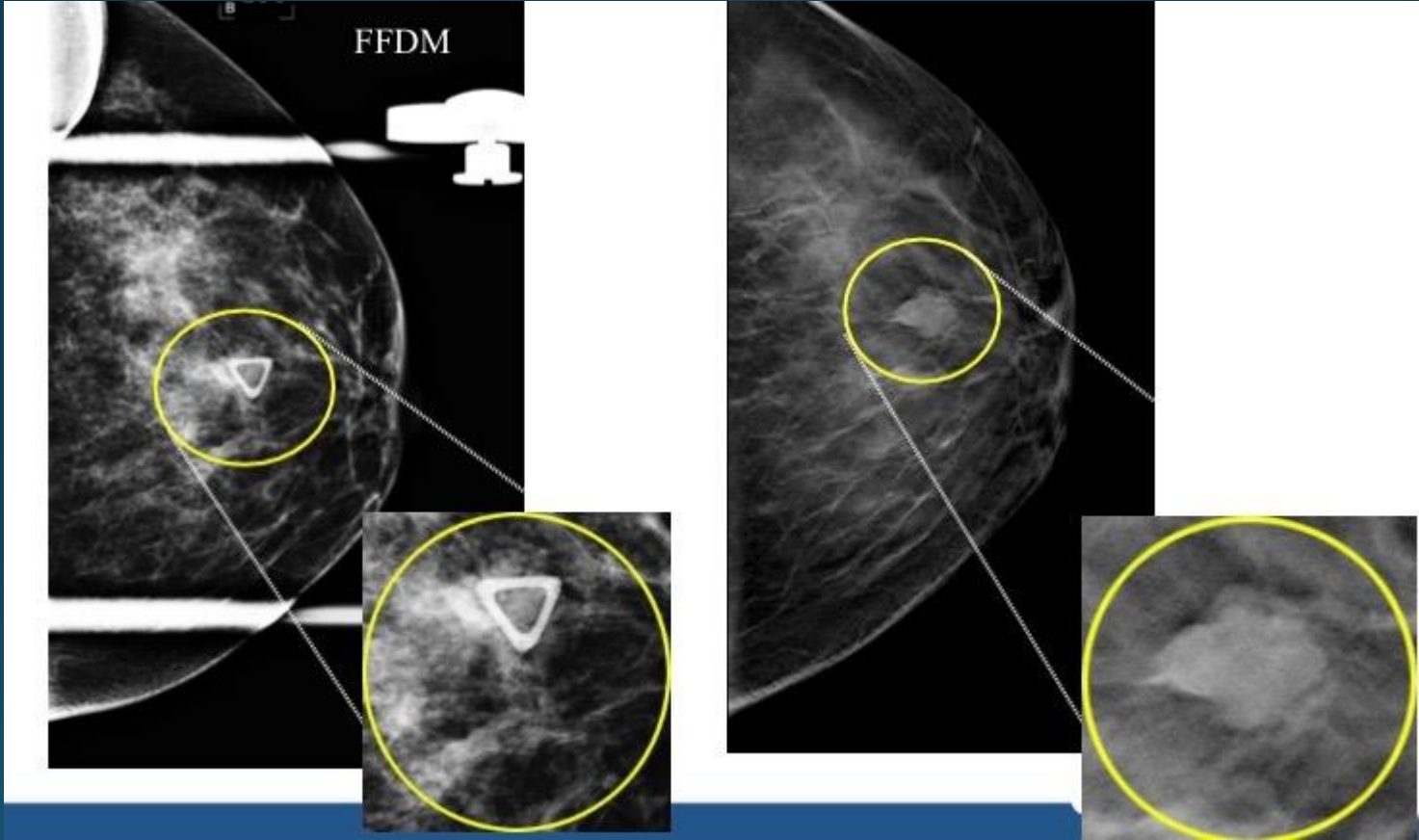
- 100 % better seen on DBT
- 73 % only seen on DBT
- Maybe one view only (CC better than MLO)

2-characterization of lesion

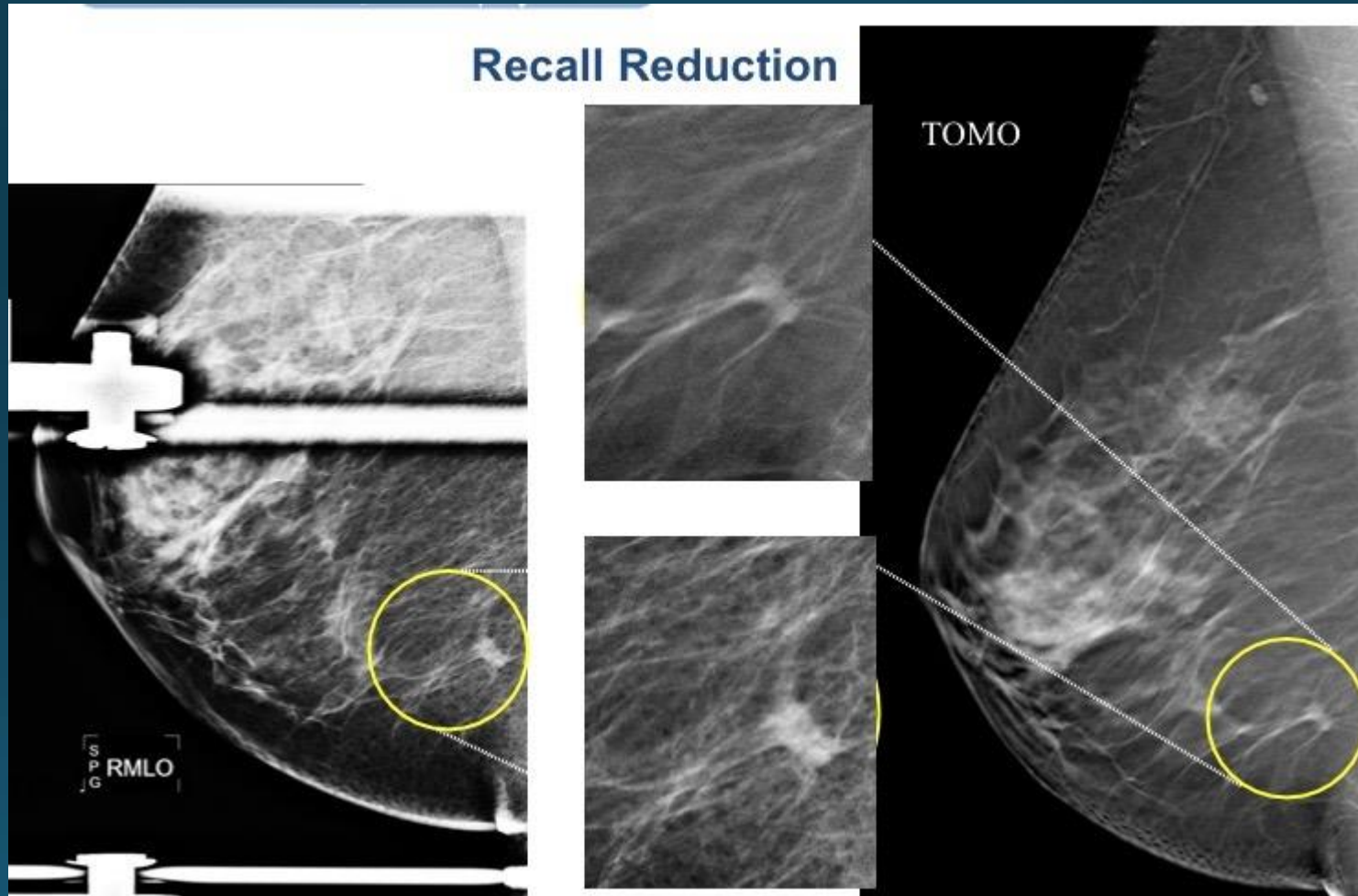


3-reduce call back (30%)



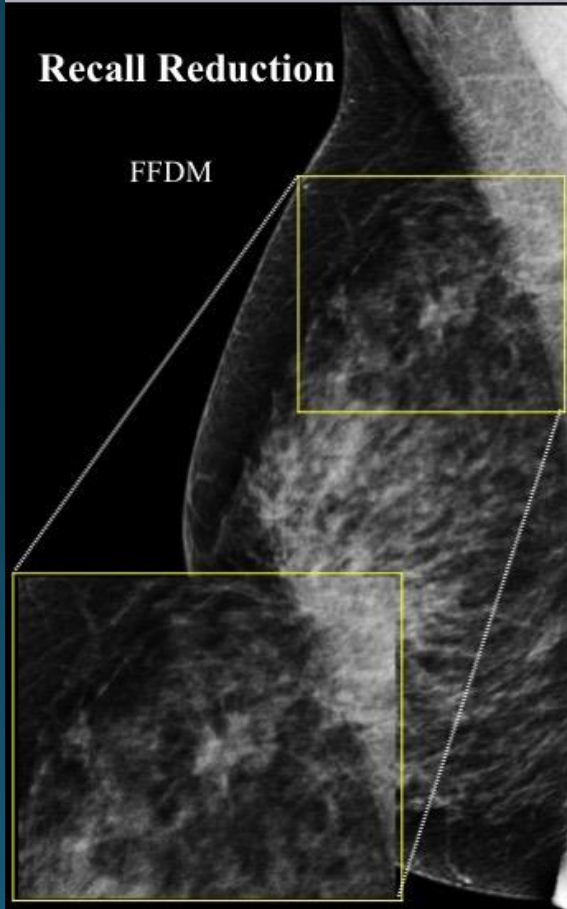


As good as spot view

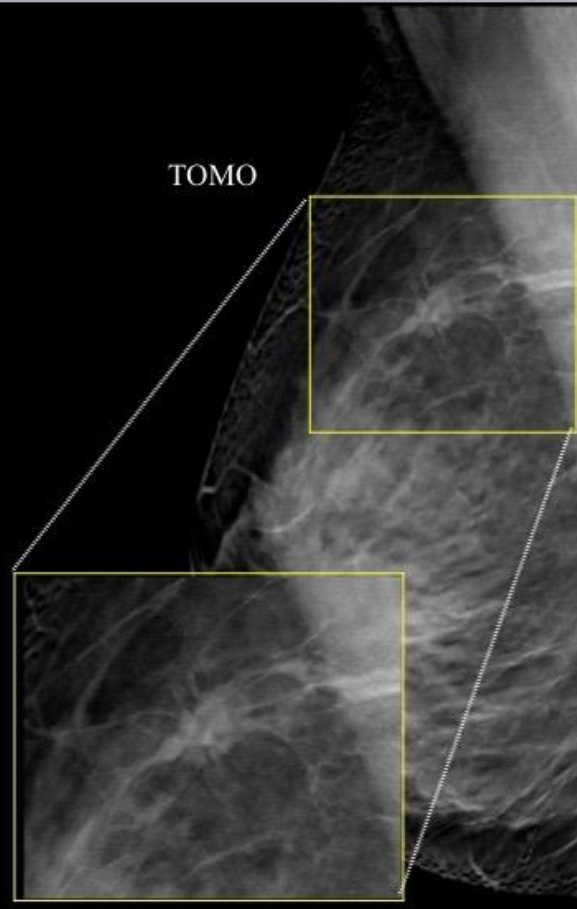


Recall Reduction

FFDM



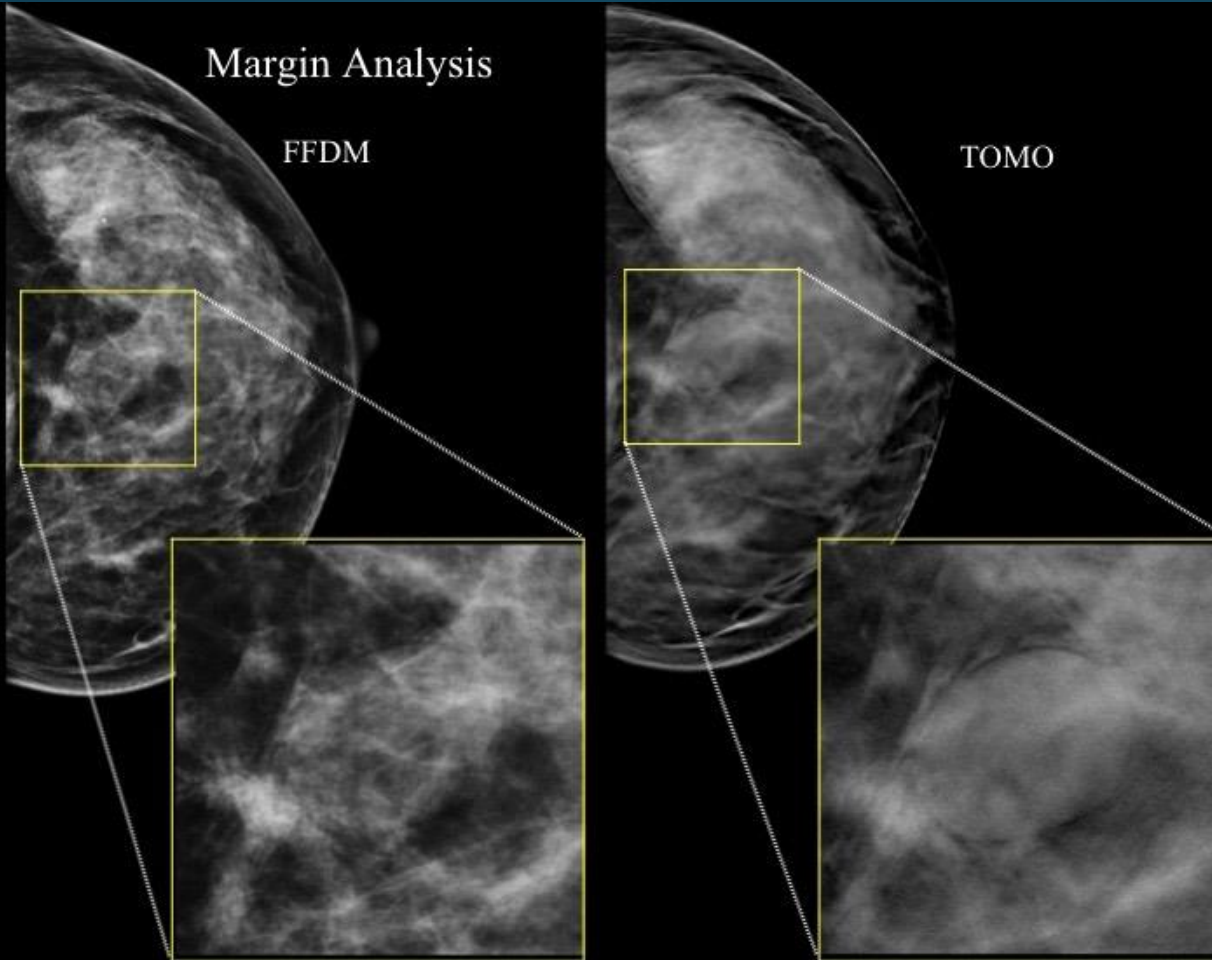
TOMO



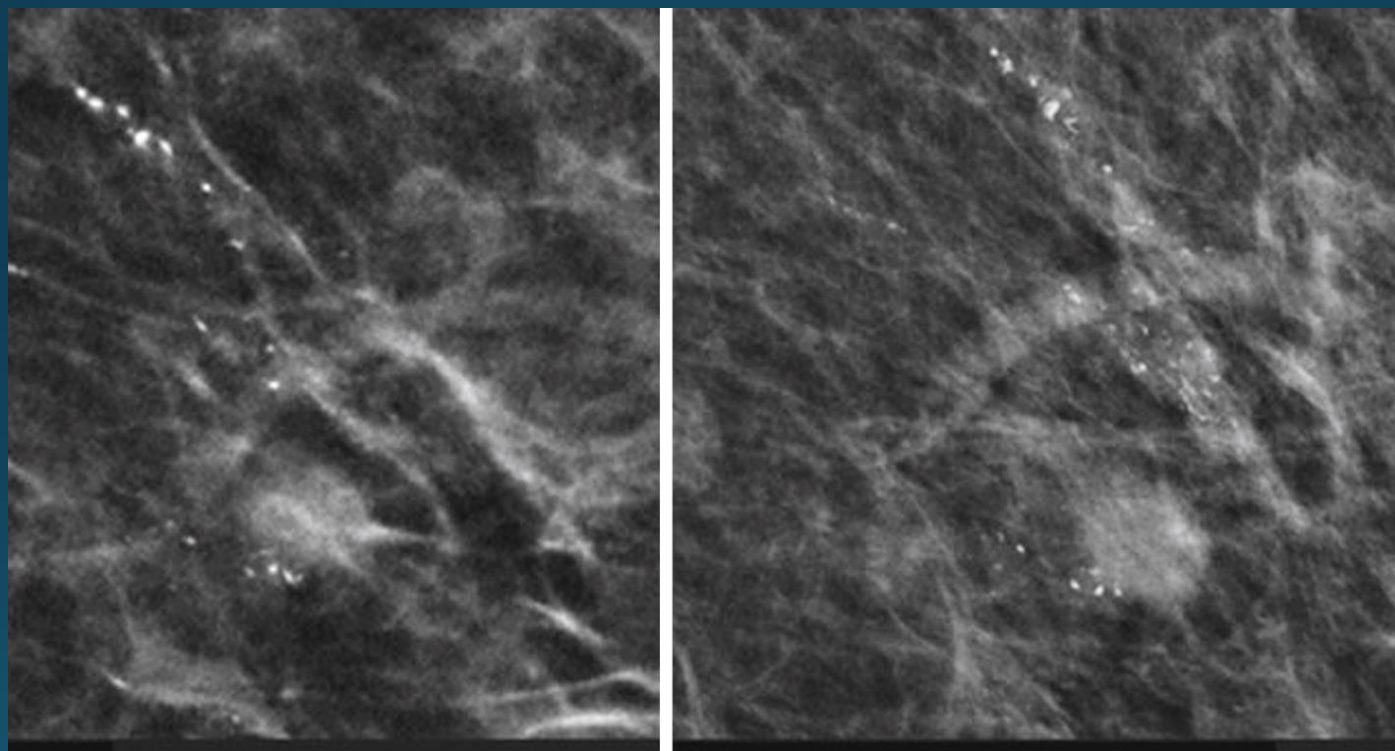
Margin Analysis

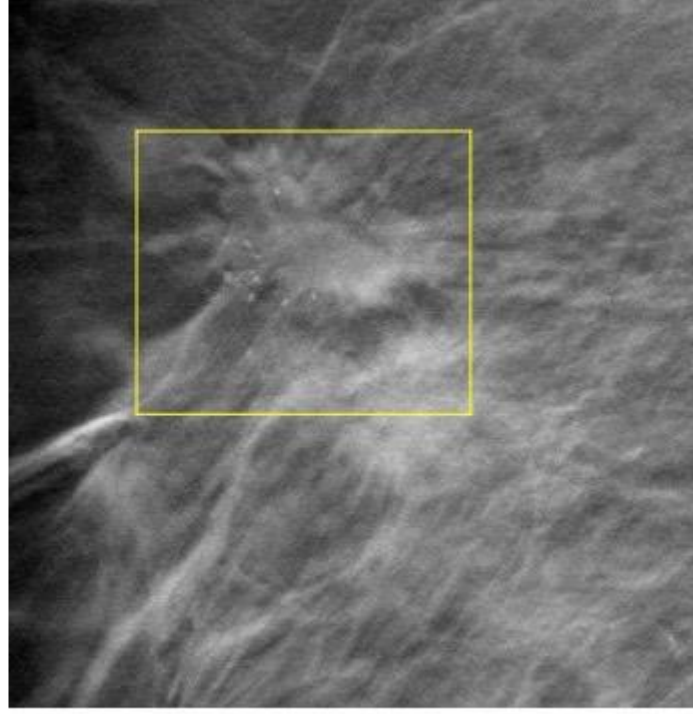
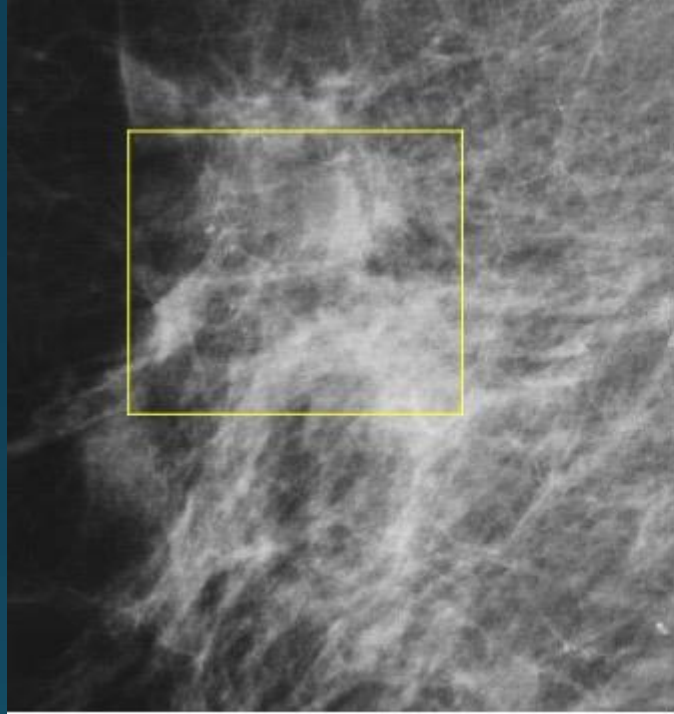
FFDM

TOMO



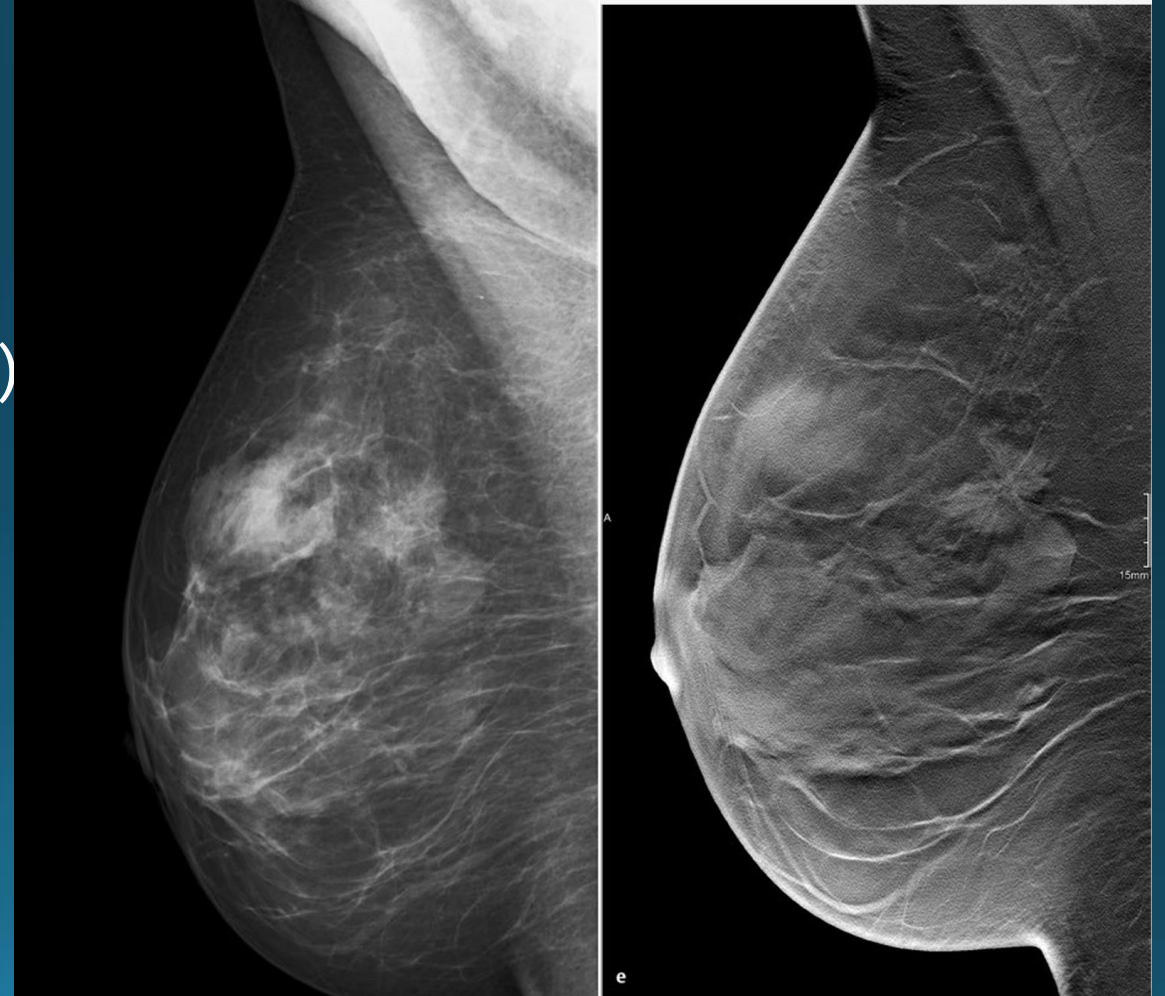
4-calcification in DBT





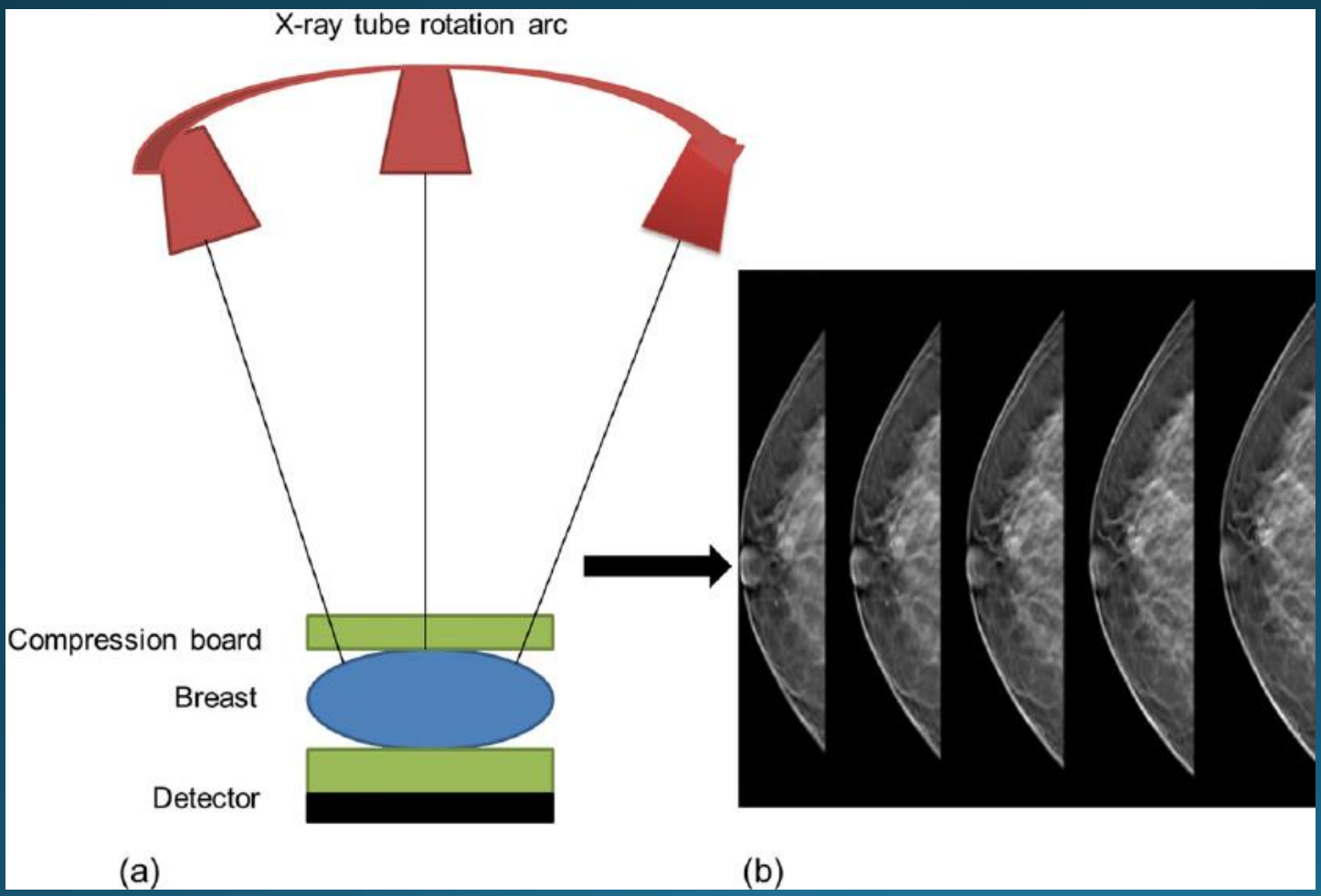
5-better detection of multicentric cancer

- Sensitivity for multifocal and Multicentric cancer is higher on DBT (63 %) Compare to mammography (21%)



DBT

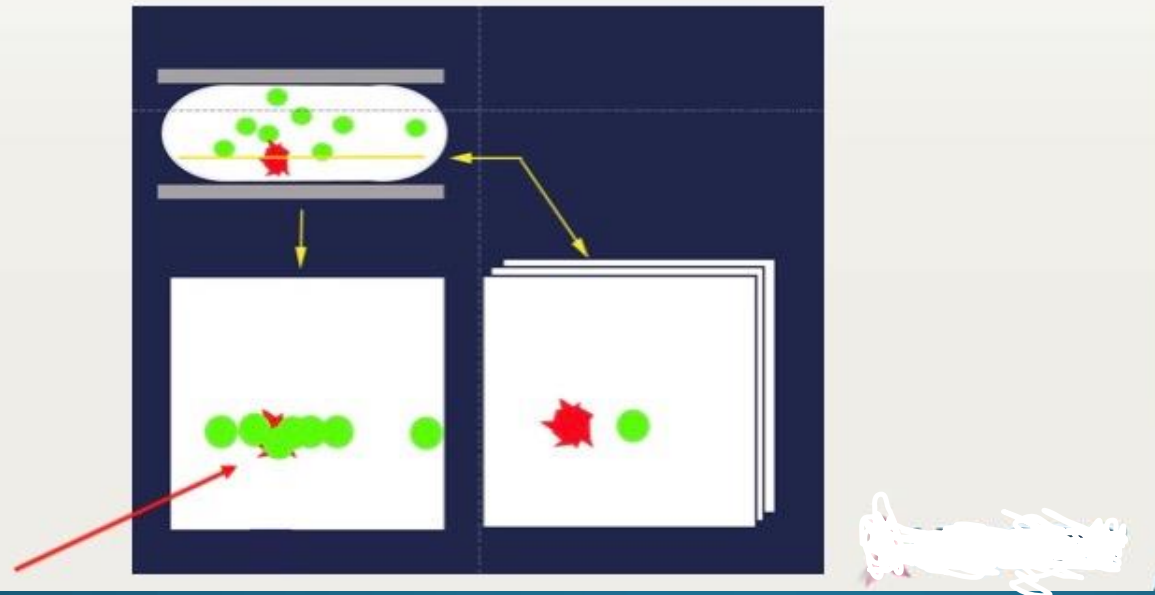
- Multiple low dose digital mammography images are obtain along an arc + reconstruction of image (3D)



Potential for Less Compression

Compression not needed to minimize tissue overlap
(structure noise)

Still need compression to reduce patient motion



DBT technique

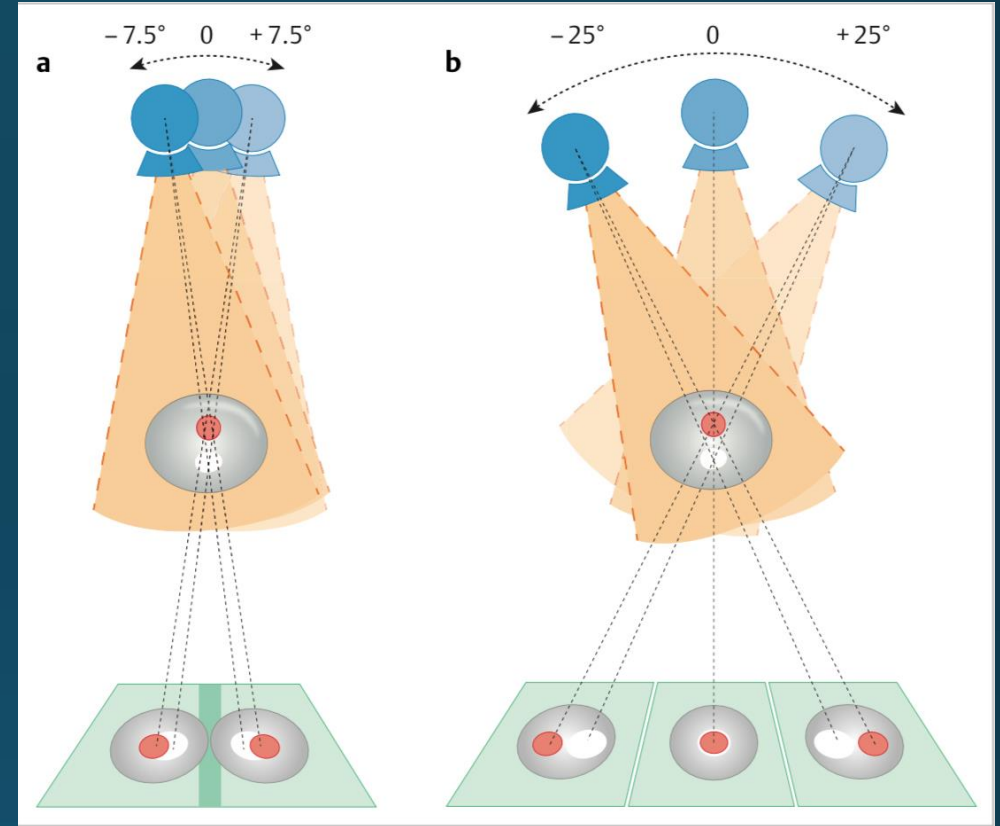
- Like tomography in plan structures are in focus , out of plan structures are blurred
- Unlike tomography , reconstructed a series of image (like CT)

DBT is not CT

- Voxels are not isotropic on DBT
- Can not product 3D reconstruction
- Can not use localizer

Sweep angle

- More exposure : less artifact
- Long scan time : more motion
- Large angle : better slice separation longer time
- Small angle : better focus per slice



Do you need 2D + 3D ?

- No (double dose)

DBT + synthetic 2D mammography (SM) vs digital mammography (2D)

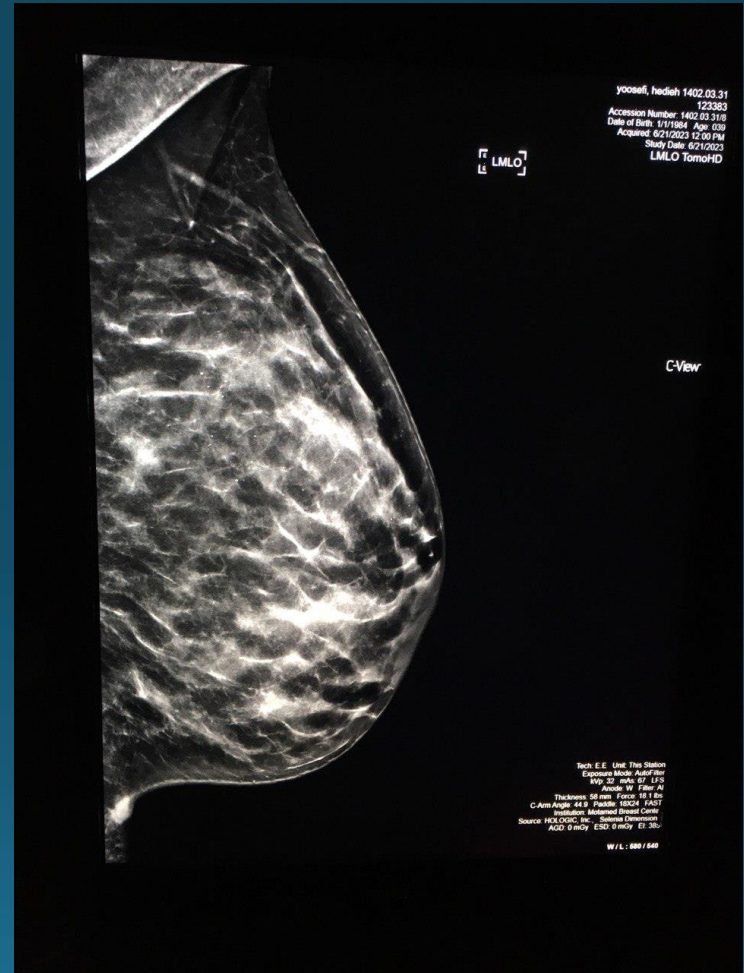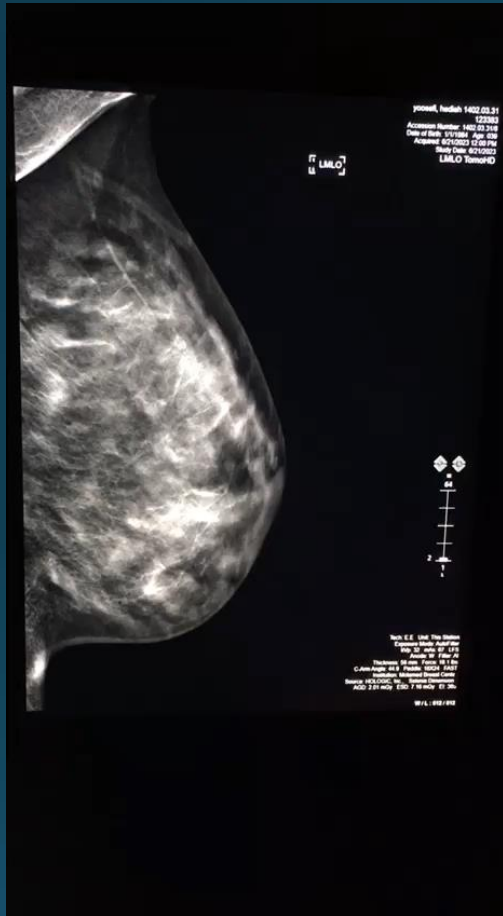
- Do we need two view on DBT ? Yes
- Calcifications on DBT require to magnification view ? Yes
- All PACS are not support DBT

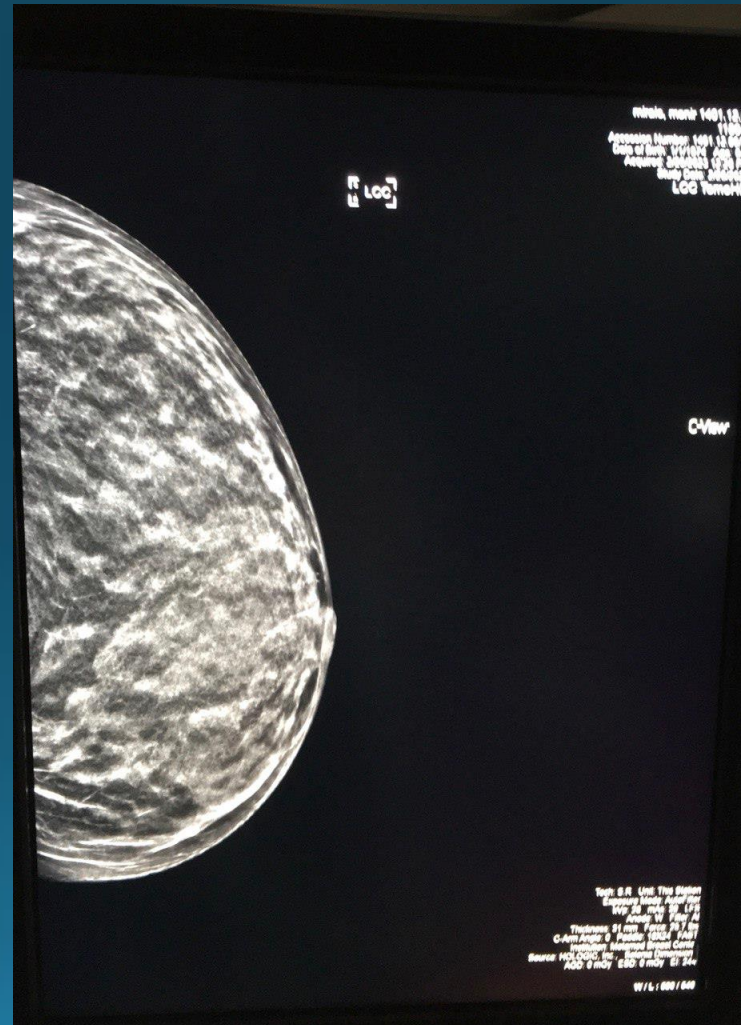
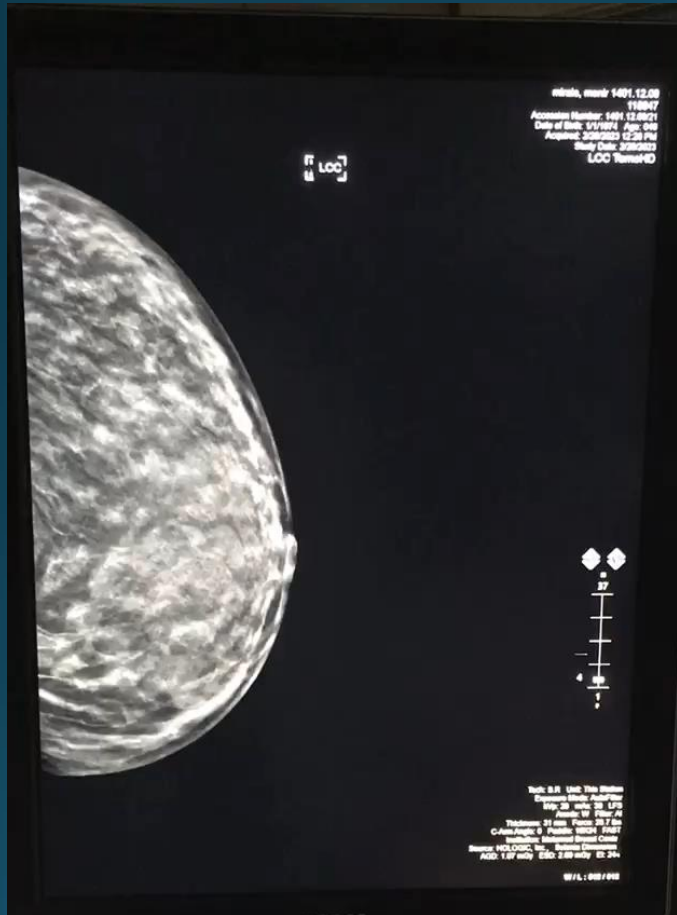
Description of lesion on DBT

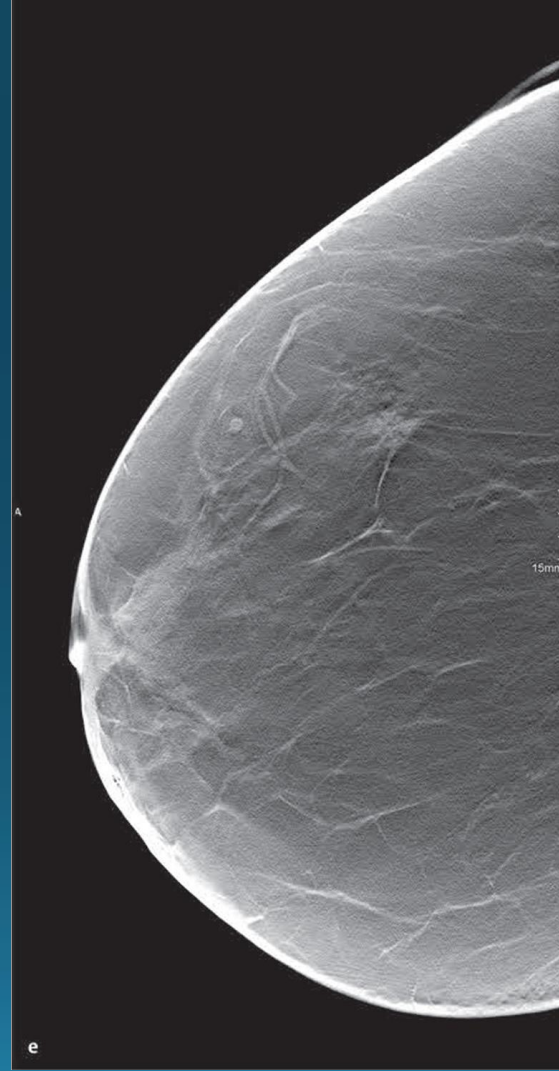
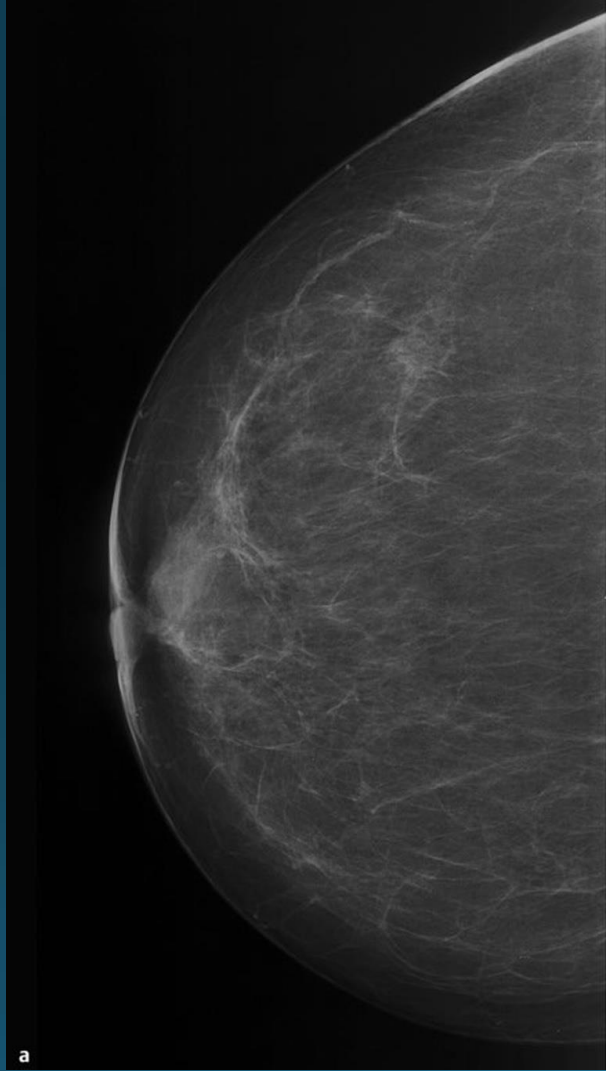
- Side , clock , depth

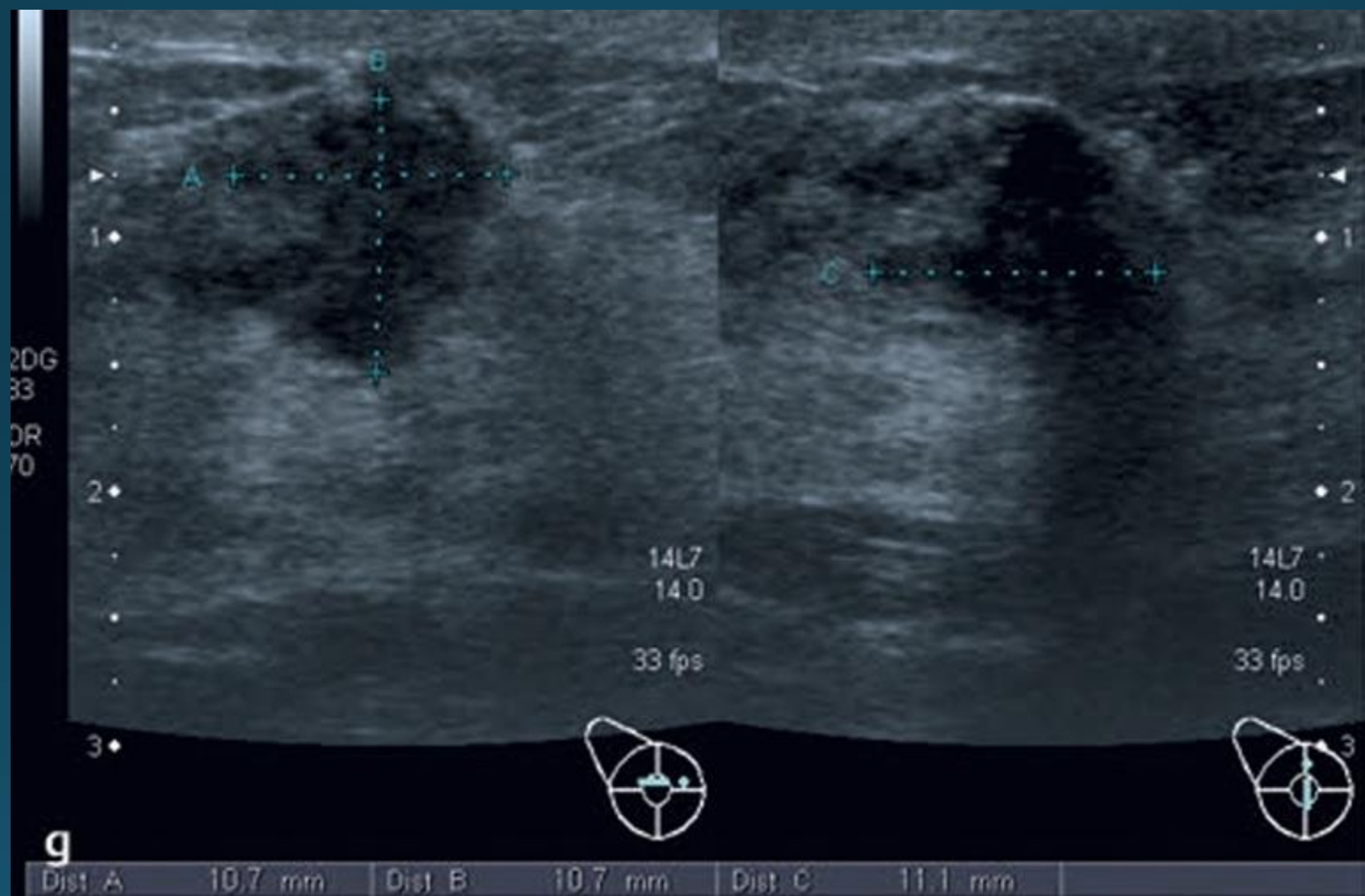
- Slice number

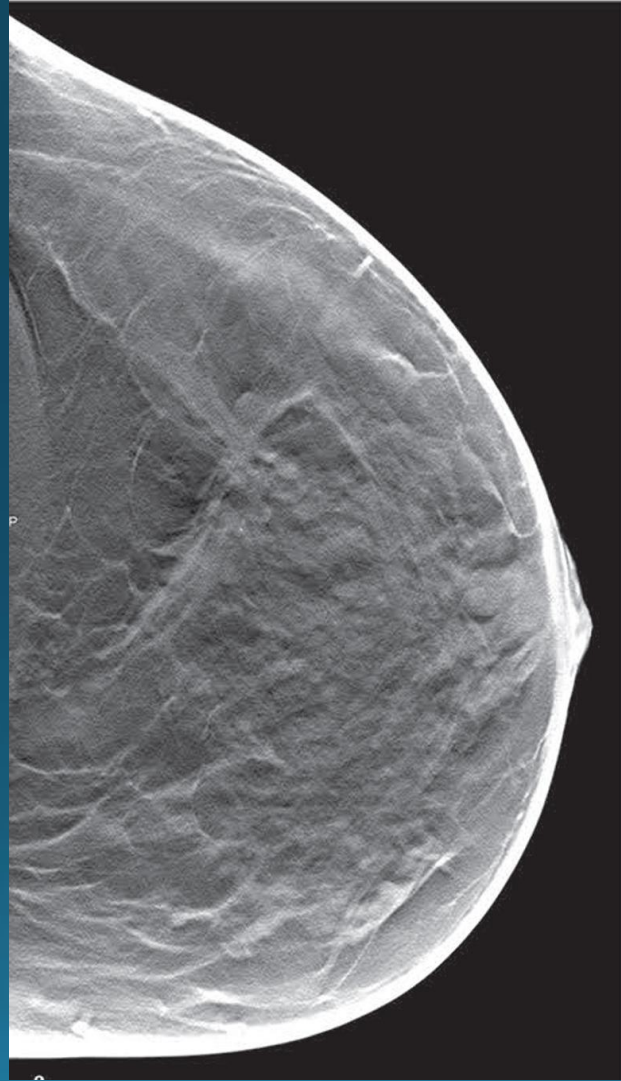
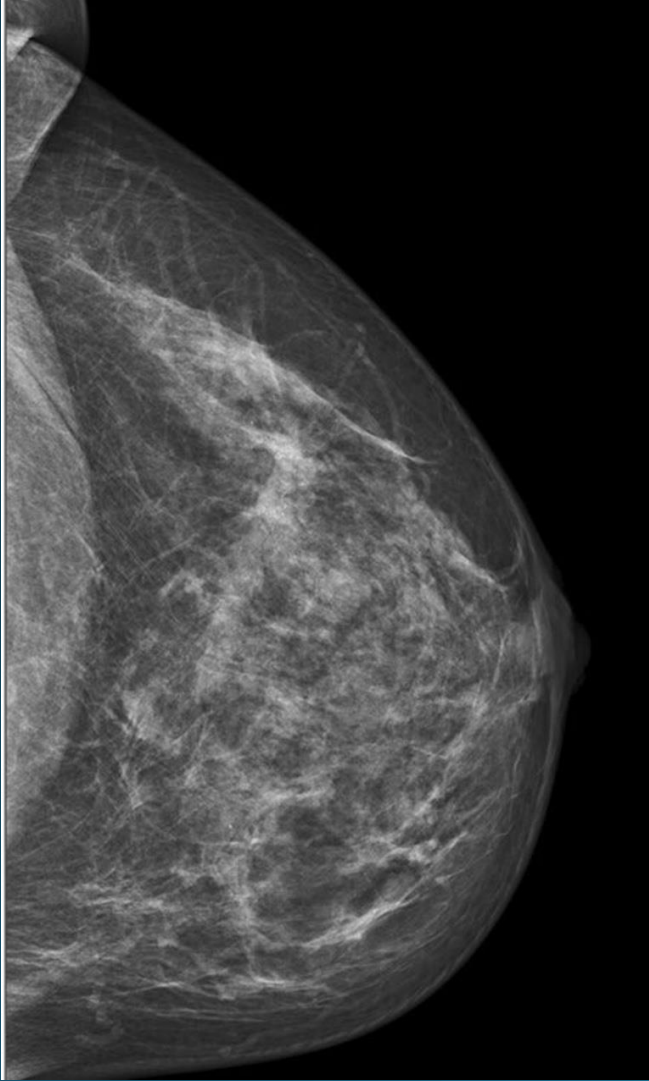
CC view slice 41/55 MLO view slice 33/55

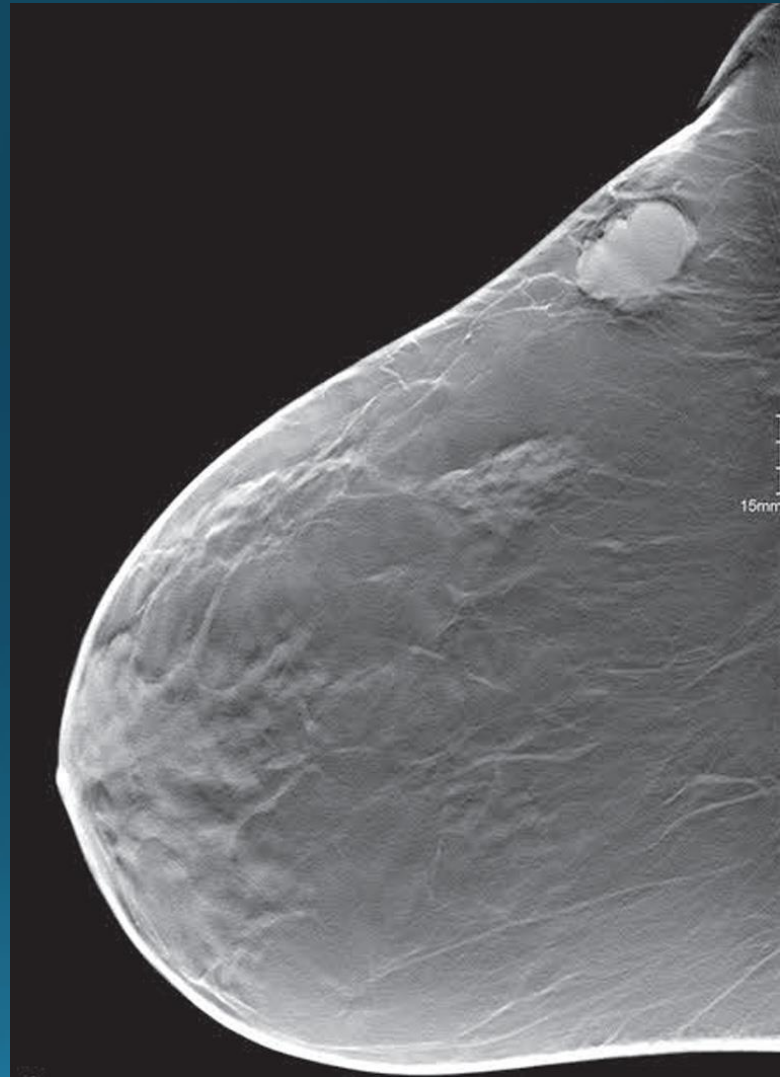
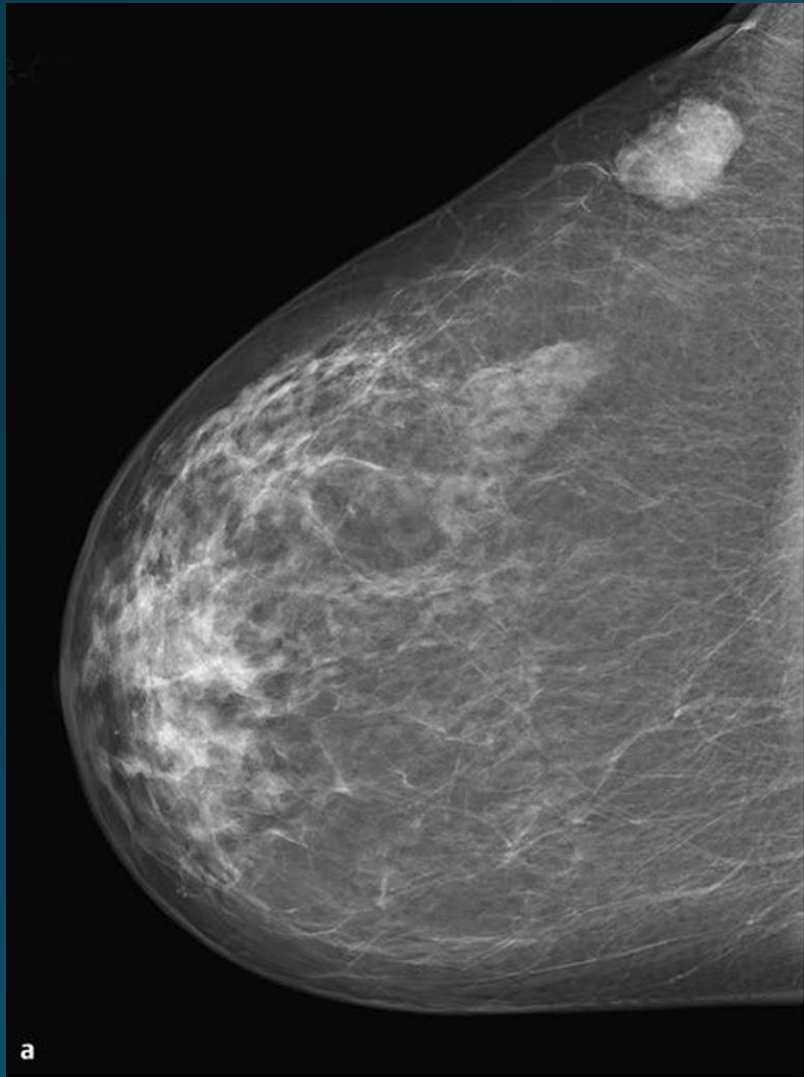












A photograph of pink cherry blossoms on a dark branch, set against a bright, slightly hazy sky. The blossoms are in various stages of opening, with some showing yellow centers. The overall mood is soft and celebratory.

THANK
YOU